



**UNIVERSIDADE FEDERAL DE CAMPINA GRANDE  
CENTRO DE SAÚDE E TECNOLOGIA RURAL  
PROGRAMA DE PÓS-GRADUAÇÃO EM CIÊNCIA E SAÚDE ANIMAL**

**KARLA PRISCILA GARRIDO BEZERRA**

**AMOSTRAS OCULARES PARA DETECÇÃO DE *LEISHMANIA SPP.* EM FELINOS  
DOMÉSTICOS E PARÂMETROS OFTÁLMICOS DE CAPRINOS MOXOTÓ E  
AVES DE RAPINA**

**PATOS - PB  
2021**

**KARLA PRISCILA GARRIDO BEZERRA**

**AMOSTRAS OCULARES PARA DETECÇÃO DE *LEISHMANIA SPP.* EM FELINOS  
DOMÉSTICOS E PARÂMETROS OFTÁLMICOS DE CAPRINOS MOXOTÓ E  
AVES DE RAPINA**

**Tese apresentada ao Programa de Pós-Graduação em Ciência e Saúde Animal do Centro de Saúde e Tecnologia Rural da Universidade Federal de Campina Grande, como requisito parcial para obtenção do título de Doutora em Ciência e Saúde Animal.**

**Orientador: Professor Dr. Almir Pereira de Souza.  
Coorientadora: Professora Dra. Ivia Carmem Talieri.**

**PATOS - PB  
2021**

B574u Bezerra, Karla Priscila Garrido.  
Amostras oculares para detecção de *Leishmania spp.* em felinos domésticos e parâmetros oftálmicos de caprinos moxotó e aves de rapina / Karla Priscila Garrido Bezerra. – Patos, 2021.  
73 f. : il. color.

Tese (Doutorado em Ciência e Saúde Animal) – Universidade Federal de Campina Grande, Centro de Saúde e Tecnologia Rural, 2021.  
"Orientação: Prof. Dr. Almir Pereira de Souza, Profa. Dra. Ivia Carmem Talieri".  
Referências.

1. Oftalmologia Veterinária. 2. Leishmaniose Felina. 3. Caprinos. 4. Aves de Rapina. 5. Testes Oftálmicos. I. Souza, Almir Pereira de. II. Talieri, Ivia Carmem. III. Título.

CDU 636.09:617.7(043)



MINISTÉRIO DA EDUCAÇÃO  
**UNIVERSIDADE FEDERAL DE CAMPINA GRANDE**  
POS-GRADUACAO EM CIENCIA E SAUDE ANIMAL

Rua Aprigio Veloso, 882, - Bairro Universitario, Campina Grande/PB, CEP 58429-900

**FOLHA DE ASSINATURA PARA TESES E DISSERTAÇÕES**

**KARLA PRISCILA GARRIDO BEZERRA**

**AMOSTRAS OCULARES PARA DETECÇÃO DE *Leishmania spp.* EM FELINOS DOMÉSTICOS E PARÂMETROS OFTÁLMICOS DE CAPRINOS MOXOTÓ E AVES DE RAPINA**

Tese apresentada ao Programa de Pós-Graduação em Ciência e Saúde Animal como pré-requisito para obtenção do título de Doutor em Ciência e Saúde Animal.

Aprovada em: 27/08/2021

**BANCA EXAMINADORA:**

Prof. Dr. Almir Pereira de Souza (Orientador - PPGCSA/UFCG)

Prof. Dr. Atticus Tanikawa (Examinador Externo - FACENE)

Prof. Dr. Antonio Fernando de Melo Vaz (Examinador Interno - UFCG)

Prof. Dr. Jeann Leal de Araújo (Examinador Externo - UFPB)

Profa. Dra. Rosangela Maria Nunes da Silva (Examinadora Externa - UFCG)

**OBSERVAÇÕES:**

- 1 - Por não possuírem cadastro como usuários externos no SEI, os examinadores Atticus Tanikawa e Jeann Leal de Araújo receberão cópia da presente Ata e darão ciência e aprovação dos termos por e-mail.
- 2 - Os examinadores internos signatários certificam que os examinadores externos acima identificados participaram da defesa da tese e tomaram conhecimento do teor deste documento.



Documento assinado eletronicamente por **ALMIR PEREIRA DE SOUZA, COORDENADOR DE POS-GRADUACAO**, em 27/08/2021, às 18:22, conforme horário oficial de Brasília, com fundamento no art. 8º, caput, da [Portaria SEI nº 002, de 25 de outubro de 2018](#).



Documento assinado eletronicamente por **ANTONIO FERNANDO DE MELO VAZ, PROFESSOR(A) DO MAGISTERIO SUPERIOR**, em 28/08/2021, às 15:39, conforme horário oficial de Brasília, com fundamento no art. 8º, caput, da [Portaria SEI nº 002, de 25 de outubro de 2018](#).



Documento assinado eletronicamente por **ROSANGELA MARIA NUNES DA SILVA, PROFESSOR 3 GRAU**, em 13/09/2021, às 09:14, conforme horário oficial de Brasília, com fundamento no art. 8º, caput, da [Portaria SEI nº 002, de 25 de outubro de 2018](#).



A autenticidade deste documento pode ser conferida no site <https://sei.ufcg.edu.br/autenticidade>, informando o código verificador **1734775** e o código CRC **3ADCA3FE**.

## AGRADECIMENTOS

Ao meu Deus, por Sua infinita bondade e misericórdia. Eu pude sentir a Tua presença em todos dias e tenho certeza que nunca me abandonastes;

Aos grandes amores da minha vida: minha família e meus animais

*– aos meus pais, Moema e Antônio: não há palavras que descrevam a minha real gratidão. Meus amores, muito obrigada pelo amor, proteção e todos os cuidados voltados a mim. Tudo por vocês, sempre. Amo infinitamente;*

*– aos meus sobrinhos, Letícia, Laura e Bento: minhas maiores alegrias e saudades mais dolorosas. Titia ama vocês, infinitamente;*

*– aos meus irmãos, Júnior e Polyana: as minhas bases de conforto. À minha gratidão por me apoiarem e me confortarem em todos os momentos. Eu sou muito realizada e grata por tê-los sempre ao meu lado. Eu amo vocês, pra sempre.*

Aos que estão aqui na terra com a gente e não para a gente: o meu amor e compaixão por vocês, animais, foi o que me trouxe até aqui. A minha alma agradece por tê-los por perto; aos que fizeram parte deste projeto, a minha eterna gratidão;

Ao meu orientador, professor Almir – agradeço imensamente por ter me aceitado como orientada e por ter apostado neste projeto. Seu poder de resolução frente aos problemas que chegavam me deu força e coragem para continuar. Como bom pesquisador, experiente, me lançou incentivos para publicar e desenvolver projetos paralelos a esta pesquisa, me inspirando a ter satisfação em fazê-los. Sou muito grata pela orientação, paciência, confiança e ensinamentos. Ao senhor, todo o meu respeito e admiração.

A minha coorientadora, professora Ivia – serei eternamente grata por tudo que me ensina e por confiar em mim. Por sua competência, me inspirou a amar a oftalmologia e a dermatologia; e a atender os animais com amor e compaixão. Serei, continuamente, admiradora da profissional e do ser humano que você é. Meus agradecimentos sempre irão se estender a sua amizade! Muito obrigada por tudo!!

Ao meu namorado, Arthur – Deus teve outros propósitos com a minha vinda para Patos e você foi o essencial. Me trouxe a paz, a paciência e o amor. Agradeço por ter se unido a mim nesta caminhada. Te amo!

À Dra. Rosileide – ser humano e profissional ímpar. Em todos os momentos em que recorri a ela, nunca me foi negada nenhuma ajuda. Seus conselhos profissionais e pessoais sempre andarão em meus pensamentos. Muita gratidão por sua amizade, Rose!

À professora Rosângela – por seu espírito acolhedor e verdadeiro. Gratidão por tê-la conhecido e por poder desfrutar do seu carinho. Sou admiradora da profissional e do ser humano que és. Obrigada por cuidar e dar amor aos animais de rua.

Aos amigos que fiz na Pós-graduação: Bea, Amanda, Dani, Janaína, Aline, Olívia, Gabi, Raquel, Thiago, Ramon, Renata e Gilzane. A vocês, o meu carinho e amor!

Aos professores que aceitaram compor à banca de defesa – professora Rosângela, professor Jeann, professor Fernando e professor Atticus. Agradeço imensamente por reservarem um tempo, em meio a tantas tarefas, para corrigirem esta tese. As contribuições de vocês serão muito valiosas.

Ao Programa de Pós-Graduação em Ciência e Saúde Animal da Universidade Federal de Campina Grande, Centro de Saúde e Tecnologia Rural, *Campus* de Patos, que me acolheu e oportunizou o desenvolvimento da nossa pesquisa para o meu doutoramento.

Ao professor Leucio pela confiança em abrir as portas do seu laboratório na UFRPE para o processamento e análise das amostras do nosso projeto. Agradeço imensamente pela receptividade.

À Adalgiza, à Adalberto e à Jonas – obrigada por estarem sempre à disposição;

Ao Hospital Veterinário, onde realizei atendimentos e parte das minhas coletas;

À Vanuza e ao Adriano da UFRPE, que ajudaram, incansavelmente, para o processamento e análises de amostras;

A todos os funcionários de limpeza do Hospital Veterinário. Agradeço pelo carinho e pelo bom trabalho feito na nossa salinha de Pós-graduação;

Aos demais técnicos e funcionários do Hospital Veterinário por estarem sempre à disposição. O trabalho de cada um foi essencial para a minha passagem por aqui;

Aos professores da Pós-graduação – agradeço imensamente a tudo o que me foi ensinado e por colaborarem para o melhoramento do nosso projeto;

À CAPES, pela bolsa de doutorado concedida;

A todos, o meu muito obrigada!

*“Agradecer também faz parte da oração”*

## RESUMO

Objetivou-se com esta pesquisa investigar a viabilidade do uso de fragmentos conjuntivais para o diagnóstico de leishmaniose em gatos e reunir dados referenciais para os testes oftálmicos em caprinos e em aves de rapina. Sendo assim, esta tese é composta por três capítulos; no capítulo I, investigou-se a ocorrência de infecção por *Leishmania* sp. em gatos, utilizando diferentes amostras biológicas e técnicas de diagnóstico. Para tanto, coletou-se variadas amostras de 16 gatos, as quais foram analisadas por diferentes métodos de diagnóstico: sangue periférico (reação em cadeia da polimerase - PCR); punção de linfonodo poplíteo direito (PCR e citologia), *swab* de pele e conjuntiva (citologia) e biópsia da conjuntiva palpebral de ambos os olhos (PCR, exame histopatológico e imunohistoquímico). Das oito amostras positivas na PCR de cinco gatos, seis (7/8 – 87,5%) eram concernentes a fragmentos conjuntivais; e uma (1/8 – 12,5%) pertencente à sangue total. A IHQ das 31 amostras de conjuntiva permitiu a identificação de 17 positivas, concernentes a 13 animais. No capítulo II, padronizou-se os valores referenciais para o teste lacrimal de Schirmer (TLS) e pressão intraocular (PIO), e descreveu a celularidade da conjuntiva ocular de caprinos Moxotó. Foram selecionados 30 caprinos adultos e 10 caprinos jovens, sadios. O valor médio obtido no TLS nos caprinos adultos foi de  $11,65 \pm 3,16$  mm/min e  $9,90 \pm 2,97$  mm/min nos jovens. A média da PIO foi de  $11,18 \pm 2,54$  mmHg nos caprinos adultos e  $10,10 \pm 2,40$  mmHg nos caprinos jovens. As amostras citológicas conjuntivais dispuseram de numerosa celularidade, revelando o mesmo padrão celular entre os caprinos jovens e adultos. O valor médio do TLS em caprinos Moxotó adultos, acima de um ano de idade, foi significativamente maior do que o de jovens com quatro meses de idade. No capítulo III, determinou-se valores referenciais para o TLS-1 e PIO; e caracterizar as células conjuntivais de águias-chilenas (*Geranaetus melanoleucus*) e gaviões-de-rabo-branco (*Geranaetus albicaudatus*). O valor médio obtido no TLS foi de  $18,33 \pm 5,46$  mm/min para as águias-chilenas e  $11 \pm 3,46$  mm/min para os gaviões-de-rabo-branco. Os valores médios da PIO foram:  $23,67 \pm 3,2$  mmHg para as águias-chilenas e  $23,5 \pm 2,59$  mmHg para os gaviões-de-rabo-branco. As análises citológicas conjuntivais revelaram numerosa celularidade e demonstraram que as células da conjuntiva das espécies estudadas possuem as mesmas características morfológicas, com predominância de células superficiais escamosas e intermediárias. Observou-se graus variados de granulação melanocítica citoplasmática em amostras do olho esquerdo de uma águia-chilena e de um gavião-de-rabo-branco. Alguns eritrócitos e agregados bacterianos foram visualizados. Ademais, uma quantidade variável de heterófilos foi constatada. Os resultados aqui obtidos irão subsidiar o diagnóstico e o tratamento adequado de afecções oculares nas espécies estudadas e em futuras investigações acerca da leishmaniose em gatos.

Palavras-chave: leishmaniose felina; caprinos; aves de rapina; testes oftálmicos.



## ABSTRACT

The objective of this research was to investigate the feasibility of using conjunctival fragments for the diagnosis of leishmaniasis in cats and to gather reference data for ophthalmic tests in goats and birds of prey. This thesis comprises three chapters; in chapter I, the occurrence of infection by *Leishmania* sp. in cats, using different biological samples and diagnostic techniques. For this purpose, several samples were collected from 16 cats, which were analyzed by different diagnostic methods: peripheral blood (polymerase chain reaction - PCR); right popliteal lymph node puncture (PCR and cytology), skin and conjunctival swab (cytology) and palpebral conjunctival biopsy of both eyes (PCR, histopathological and immunohistochemical examination). Of the eight PCR positive samples from five cats, six (7/8 – 87.5%) concerned conjunctival fragments; and one (1/8 – 12.5%) belonging to whole blood. The IHC of the 31 conjunctival samples allowed the identification of 17 positives, concerning 13 animals. In chapter II, the reference values for Schirmer tear test (TLS) and intraocular pressure (IOP) were standardized, and the cellularity of the ocular conjunctiva of Moxotó goats was described. Thirty adult goats and 10 healthy young goats were selected. The mean value obtained in the TLS in adult goats was  $11.65 \pm 3.16$  mm/min and  $9.90 \pm 2.97$  mm/min in young goats. The mean IOP was  $11.18 \pm 2.54$  mmHg in adult goats and  $10.10 \pm 2.40$  mmHg in young goats. The conjunctival cytological samples had numerous cellularity, revealing the same cellular pattern between young and adult goats. The mean value of TLS in adult Moxotó goats, above one year of age, was significantly higher than that of young ones with four months of age. In chapter III, reference values for TLS and PIO were determined; the ocular bacterial microbiota was described and the conjunctival cells in birds of prey were characterized. In chapter III, reference values for TLS-1 and PIO were determined; and characterize the conjunctival cells of black-chested Buzzard-eagle (*Geranaetus melanoleucus*) and white-tailed hawks (*Geranaetus albicaudatus*). The mean value found in the TLS was  $18.33 \pm 5.46$  mm / min for the Chilean eagles and  $11 \pm 3.46$  mm / min for the white-tailed hawks. The mean IOP values were:  $23.67 \pm 3.2$  mmHg for the Chilean eagles and  $23.5 \pm 2.59$  mmHg for the white-tailed hawks. The conjunctival cytological analysis revealed numerous cellularity and demonstrated that the conjunctival cells of the studied species have the same morphological characteristics, with a predominance of squamous and intermediate superficial cells. Varying degrees of cytoplasmic melanocytic granulation in h were observed in the left eye of a Chilean eagle and a white-tailed hawk. Some erythrocytes and bacterial aggregates were visualized. Furthermore, a variable variable of heterophils was found. The results here gain support for the diagnosis and proper treatment of eye disorders in the species studied and in future investigations about leishmaniasis in cats.

Keywords: feline leishmaniasis; goats; birds of prey; ophthalmic tests.

## LISTA DE ILUSTRAÇÕES

### CAPÍTULO II

#### Characterization of conjunctival cells and determination of reference values for ophthalmic tests in Moxotó goats

	<b>Pág.</b>
<b>Figure 1.</b> Conjunctival cytology of a healthy Moxotó goat ( <i>Capra aegagrus hircus</i> ). Detail of 1 the predominance of superficial epithelial cells (asterisk); in a smaller number, the squamous 2 epithelial cells (big arrow) and basal cell (small arrow) are observed. Diff Quick-3 Panoptic.Obj.40x), [Bar = 50µm].....	55

### CAPÍTULO III

#### Reference values for ophthalmic diagnostic tests and conjunctival cell characterization of black-chested buzzard-eagles (*Geranaetus melanoleucus*) and white-tailed hawks (*Geranaetus albicaudatus*)

	<b>Pág.</b>
<b>Figure 1.</b> (A-C) Ophthalmic tests on white-tailed hawk ( <i>Geranaetus albicaudatus</i> ), healthy, resident at the Parque Zoobotânico Arruda Câmara, João Pessoa, Paraíba, Brazil. (A) Schirmer's tear test (B) exfoliative conjunctival cytology (C) applanation tonometry.....	70
<b>Figure 2.</b> Conjunctival cytology of a healthy white-tailed hawk ( <i>Geranaetus albicaudatus</i> ). A variable amount of heterophils is observed. Diff Quick-Panoptic.Obj.100x. ....	71

## LISTA DE TABELAS

### CAPÍTULO I

#### Use of Conjunctival Fragments to Detect *Leishmania* sp. in Domestic Cats from the Region of Sertão in Paraíba, Brazil

	<b>Pág.</b>
<b>Table 1.</b> Distribution of PCR and IHC results in the detection of <i>Leishmania</i> sp., with their respective samples analyzed and clinical signs and/or concomitant diseases identified in 16 domestic cats in the municipality of Patos, Paraíba, Brazil .....	37

### CAPÍTULO II

#### Characterization of conjunctival cells and determination of reference values for ophthalmic tests in Moxotó goats

	<b>Pág.</b>
<b>Table 1.</b> Mean and standard deviation for tear production, obtained by Schirmer's tear test, and intraocular pressure in young and adult Moxotó goats .....	54

### CAPÍTULO III

#### Reference values for ophthalmic diagnostic tests and conjunctival cell characterization of black-chested buzzard-eagles (*Geranaetus melanoleucus*) and white-tailed hawks (*Geranaetus albicaudatus*)

	<b>Pág.</b>
<b>Tabela 1.</b> Mean and standard deviation for Schirmer's tear test and intraocular pressure in black-chested buzzard-eagles ( <i>Geranaeus melanoleucus</i> ) and white-tailed hawks ( <i>Geranaetus albicaudatus</i> ) .....	72

## SUMÁRIO

	Pág
RESUMO .....	8
ABSTRACT .....	9
LISTA DE ILUSTRAÇÕES .....	10
LISTA DE TABELAS .....	11
<b>1. INTRODUÇÃO GERAL .....</b>	<b>14</b>
<b>2. REFERÊNCIAS .....</b>	<b>15</b>
<b>3. CAPÍTULO I .....</b>	<b>17</b>
<b>Use of Conjunctival Fragments to Detect <i>Leishmania</i> sp. in Domestic Cats from the Region of Sertão in Paraíba, Brazil</b>	
ABSTRACT .....	18
1. Introduction .....	19
2. <b>Materials and methods</b> .....	21
2.1. <i>Animals</i> .....	21
2.2. <i>Clinical evaluation</i> .....	21
2.3. <i>Collection of biological samples</i> .....	21
2.4. <i>Cytological analysis</i> .....	23
2.5. <i>Histopathological analysis</i> .....	23
2.6. <i>DNA extraction</i> .....	23
2.7. <i>Polymerase Chain Reaction (PCR)</i> .....	23
2.8. <i>Immunohistochemistry</i> .....	24
3. Results .....	24
4. Discussion.....	25
5. Conclusion .....	28
References .....	29
<b>4. CAPÍTULO II .....</b>	<b>39</b>
<b>Characterization of conjunctival cells and determination of reference values for ophthalmic tests in Moxotó goats</b>	
ABSTRACT .....	40
RESUMO .....	41
INTROCTION .....	42
MATERIAL AND METHODS .....	43
<i>Animals</i> .....	43
<i>Schirmer's tear test-1 (STT-1)</i> .....	44
<i>Intraocular pressure (IOP)</i> .....	44
<i>Conjunctival cytology</i> .....	44
<i>Statistical analysis</i> .....	44
RESULTS .....	44
<i>Schirmer's tear test-1 (STT-1)</i> .....	44
<i>Intraocular pressure (IOP)</i> .....	45
<i>Conjunctival cytology</i> .....	45
DISCUSSION.....	45
CONCLUSION .....	47
REFERENCES .....	48
<b>5. CAPÍTULO III.....</b>	<b>56</b>

**Reference values for ophthalmic diagnostic tests and conjunctival cell characterization of black-chested buzzard-eagles (*Geranaetus melanoleucus*) and white-tailed hawks (*Geranaetus albicaudatus*)**

ABSTRACT .....	57
RESUMO .....	58
INTRODUCTION.....	59
MATERIAL AND METHODS .....	60
Ethics statement .....	60
Animals .....	61
Eye exam .....	61
Schirmer 1 tear test (STT-1).....	61
Intraocular pressure (IOP) .....	61
Conjunctival cytology .....	61
RESULTS .....	62
Schirmer 1 tear test (STT-1) .....	62
Intraocular pressure (IOP).....	62
Conjunctival cytology.....	62
DISCUSSÃO .....	62
CONCLUSÃO .....	64
REFERÊNCIAS .....	65
<b>6. CONCLUSÕES GERAIS .....</b>	<b>73</b>

## 1. INTRODUÇÃO GERAL

O sistema visual é substancial para os animais domésticos, silvestres, selvagens e exóticos; assim, qualquer eventualidade que culmine no comprometimento ou perda da visão implicará em incapacidade de sobrevivência em vida livre ou limitar a qualidade de vida em cativeiro. A oftalmologia é uma especialidade que atrai o interesse de clínicos veterinários, o que alerta a necessidade de literatura especializada, fato que motiva os pesquisadores a desenvolverem estudos que forneçam informações com aplicabilidade clínica na área supradita. A literatura científica dispõe de dados básicos consolidados sobre a fisiologia ocular de várias espécies; contudo, no tocante de algumas aves rapinantes e de caprinos nativos ainda são incipientes.

A oftalmologia também tem grande importância em investigações referentes ao diagnóstico de doenças infecciosas, como a leishmaniose. Embora se saiba do valor das amostras oculares para o diagnóstico da infecção em cães, pouco se conhece sobre a importância no que diz respeito aos gatos. Alguns estudos vêm mostrando a alta prevalência de alterações oftálmicas em felinos com leishmaniose (CHATZIS et al., 2014; HERVÁS et al., 2001; LEIVA et al., 2005; PENNISI et al., 2004; POLI et al., 2002; VERNEUIL, 2013), fortalecendo a hipótese de que as amostras oculares sejam valiosas para a detecção de *Leishmania* sp. nesta espécie. Para tanto, tornam-se necessárias avaliações mais acuradas dessas amostras por meio de diferentes técnicas de diagnóstico. Tal descoberta facilitaria futuras investigações epidemiológicas acerca do papel dos gatos nesta doença.

Estudos oftalmológicos com caprinos tem sido infrequentes (BROADWATER et al., 2007), principalmente no que concerne as raças caprinas nativas. Isto, possivelmente, se deve ao fato desses animais pertencerem, em quase sua totalidade, a região Nordeste do Brasil. É importante destacar que eles possuem grande valor cultural e econômico para a referida região e estão ameaçados devido ao cruzamento demasiado com raças exóticas, requerendo maior atenção aos cuidados veterinários (SANTOS et al., 2013). Desta forma, reunir dados referenciais para os testes oftálmicos de rotina será de grande valia para os programas de conservação de recursos genéticos, bem como para a identificação de modelos experimentais em estudos de oftalmologia comparada.

Para as aves de rapina, o olho é o órgão sensorial que possui maior importância e, ainda assim, há poucas investigações acerca de valores referenciais para teste básicos de diagnóstico oftálmico para algumas espécies, dificultando o avanço na melhoria de atendimentos das afecções oculares.

A carência de dados básicos referenciais para os testes oftálmicos dificulta o diagnóstico e o tratamento adequado das afecções oculares, apesar das contribuições obtidas para outras espécies de rapinantes (BARSOTTI et al., 2013; HARRIS et al., 2008; KUHN et al., 2013; RODARTE-ALMEIDA et al., 2013) e de caprinos (BROADWATER et al., 2007; RIBEIRO et al., 2010); os valores basais fisiológicos de testes oftálmicos aplicáveis para estas espécies não auxiliam o diagnóstico das afecções oculares em águias-chilenas (*Geranaetus melanoleucus*), gaviões-do-rabo-branco (*Geranaetus albicaudatus*) e de caprinos Moxotó, respectivamente; tendo em vista que os valores do teste lacrimal de Schirmer e pressão intraocular variam, consideravelmente, entre as espécies, bem como entre indivíduos da mesma família, não podendo ser extrapolados mesmo entre espécies intimamente correlacionadas (OFRI et al., 2002).

Diante das lacunas do conhecimento oftálmico de todo o contexto acima, objetivou-se com esta tese investigar a viabilidade do uso de fragmentos conjuntivais para detecção de *Leishmania* spp. em gatos de uma região endêmica, utilizando diferentes técnicas de diagnóstico, bem como reunir dados básicos referenciais para os testes oftálmicos de rotina em caprinos Moxotó e em aves de rapina – águias-chilenas (*Geranaetus melanoleucus*) e gaviões-do-rabo-branco (*Geranaetus albicaudatus*).

## 2. REFERÊNCIAS

- BARSOTTI, G. *et al.* Schirmer tear test type I readings and intraocular pressure values assessed by applanation tonometry (Tonopen® XL) in normal eyes of four European species of birds of prey. **Veterinary Ophthalmology**, v. 16, n. 5, p. 365-366, 2013.
- BROADWATER J. J. *et al.* Ophthalmic examination findings in adult pygmy goats (*Capra hircus*). **Veterinary Ophthalmology**, v. 10, n. 5, p. 269-273. 2007.
- CHATZIS M.K. *et al.* 2014. Cytological and molecular detection of *Leishmania infantum* in different tissues of clinically normal and sick cats. **Veterinary Parasitology**, v. 202, n. 2-4, p. 217-225. 2014.
- HARRIS, M. C. *et al.* Ophthalmic examination findings in a colony of Screech owls (*Megascops asio*). **Veterinary Ophthalmology**, v. 11, n. 3, p. 186-192, 2008.

HERVÁS, J. *et al.* Granulomatous (pseudotumoral) iridiocyclitis associated with leishmaniasis in a cat. **Veterinary Record**, v. 149, n. 20, p. 624-625, 2001.

KUHN, S. E. *et al.* Normal Ocular Parameters and Characterization of Ophthalmic Lesions in a Group of Captive Bald Eagles, **Journal of Avian Medicine and Surgery**, v. 27, n. 2, p. 90-98, 2013.

LEIVA, M. *et al.* Therapy of ocular and visceral leishmaniasis in a cat. **Veterinary Ophthalmology**, v. 8, n. 1, p. 71-75, 2005.

OFRI R. *et al.* Intraocular pressure and tear production in five herbivorous wildlife species. **Veterinary Record**, v. 151, n. 9, p. 265-268. 2002.

PENNISI, M. G. *et al.* Case report of leishmaniasis in four cats. **Veterinary Research Communications**, v. 28, n. 1, p. 363-366, 2004.

POLI, A. *et al.* Feline leishmaniasis due to *Leishmania infantum* in Italy. **Veterinary Parasitology**, v. 106, n. 3, p. 181-191, 2002.

RIBEIRO A.P. *et al.* Intraocular pressure and tear secretion in Saanen goats with different ages. *Pesquisa Veterinária Brasileira*, v. 30, n. 9, p. 798-802, 2010.

RODARTE-ALMEIDA A. C. V. *et al.* O olho da coruja-orelhuda: observações morfológicas, biométricas e valores de referência para testes de diagnóstico oftálmico. **Pesquisa Veterinária Brasileira**, v. 33, n. 10, p. 1275-1289. 2013.

SANTOS R. P. *et al.* Identification of naturalized goat breeds under conservation from ortheastern Brazil using chromosomal markers. **Genetics and Molecular Research**, v. 12, n. 3, p. 3193-3200, 2013.

VERNEUIL, M. Leishmaniose oculaire féline: à propos d'un cas. **Journal Français d'ophtalmologie**, v. 36, n. 4, p. 67-72, 2013.



**CAPÍTULO I:**

**Use of Conjunctival Fragments to Detect *Leishmania* sp. in Domestic Cats from the Region of Sertão in Paraíba, Brazil**

Artigo submetido ao periódico *Veterinary Parasitology: Regional Studies and Reports*  
Qualis A3

**Use of Conjunctival Fragments to Detect *Leishmania* sp. in Domestic Cats from the Region of Sertão in Paraíba, Brazil**

Karla Priscila Garrido Bezerra<sup>a,\*</sup>, priscilagarridomv@gmail.com (, Leucio Câmara Alves<sup>b</sup>, Carlos Adriano de Santana Leal<sup>b</sup>, Antônio Flávio Medeiros Dantas<sup>a</sup>, Jacilene Lourenço Silva<sup>c</sup>, Maria Vanuza Nunes de Meireles<sup>c</sup>, Millena de Oliveira Firmino<sup>a</sup>, Lylian Karlla Gomes de Medeiros<sup>a</sup>, Ivya Carmem Talieri<sup>d</sup> e Almir Pereira de Souza<sup>a</sup>

<sup>a</sup> Programa de Pós-Graduação em Ciência e Saúde Animal., Universidade Federal de Campina Grande, Centro do Saúde e Tecnologia Rural, Avenida Universitária, s/n - Santa Cecília, Patos, PB, 58708-110, Brasil.

<sup>b</sup> Departamento de Medicina Veterinária, Universidade Federal Rural Pernambuco (UFRPE), Rua Dom Manuel de Medeiros, s/n - Dois Irmãos, Recife - PE, 52171-900, Brasil.

<sup>c</sup> Programa de Pós-Graduação em Ciência Animal Tropical, UFRPE.

<sup>d</sup> Departamento de Medicina Veterinária, Universidade Federal da Paraíba, Campus II, 12 Rodovia, PB-079, Areia - PB, 58397-000, Brasil.

\*Corresponding author.

**ABSTRACT**

Leishmaniasis is an endemic zoonotic disease, considered a relevant public health problem in Brazil. Although dogs are considered the most important reservoir host for *Leishmania infantum*, a parasite that causes zoonotic visceral leishmaniasis, cats are believed to play a significant role in the disease cycle. Therefore, the objective was to investigate the occurrence of infection by *Leishmania* sp. in cats from an endemic region, using different biological samples and diagnostic techniques. For this purpose, several samples were collected from 16 cats, which were analyzed by different diagnostic methods, as peripheral blood (PCR); puncture of the right popliteal lymph node (PCR and cytology), skin and conjunctiva swab (cytology), and biopsy of the palpebral conjunctiva from both eyes (PCR, histopathological and immunohistochemical examination). Histopathological analysis of the conjunctiva and cytological analysis of the skin, conjunctiva, and lymph node has not revealed the presence of amastigote forms of *Leishmania* sp. Of the 16 animals evaluated, four (4/16 – 25%) tested positive, both in the PCR and immunohistochemistry (IHC) technique. The PCR test has detected eight positive samples for *Leishmania infantum*, corresponding to five cats, out of the 16 tested (5/16 – 31.25%). Of the eight positive samples, six (7/8 – 87.5%) were related to

conjunctival fragments; and one (1/8 – 12.5%) to whole blood. The IHC of the 31 conjunctival samples allowed the identification of 17 positives, concerning 13 animals (13/16 – 81.25%). Concomitant diseases and/or systemic, ophthalmic, and dermatological clinical signs were found in four (4/5) PCR-positive animals, and in eight (8/13) IHC-positive ones. Given the findings, it is concluded that the conjunctival tissue has relevant diagnostic value, considering that the positive results for *Leishmania* sp. were based mostly on it. Therefore, it should be considered for analyzes using IHC and PCR in future investigations about leishmaniasis in cats. In addition, the results obtained highlight the need for the use of multiple techniques to obtain the diagnosis of the disease in felines.

Keywords: feline leishmaniasis, conjunctiva, PCR, immunohistochemistry, cytology, histopathology

## **Introduction**

Leishmaniasis is referred to as one of the "neglected tropical diseases", being a relevant public health problem in Brazil due to its wide incidence and geographic distribution (Bern et al., 2008, Alvar et al., 2012). It is a zoonotic endemic disease, that has a protozoan of the genus *Leishmania* (*L.*) as an etiological agent, which is transmitted during the blood meal of female arthropod vectors of the genus *Phlebotomus* in the Old World and *Lutzomyia* in the New World (Gramiccia 2011), with the species *Lutzomyia longipalpis* being the most relevant in Brazil (Laison and Rangel, 2005).

Among the species that can be naturally infected, the domestic dog is considered the most relevant domestic/peridomestic reservoir host of the parasite that causes zoonotic visceral leishmaniasis – *L. infantum* (Laison and Rangel, 2005; Baneth et al., 2008; Noli and Saridomichelakis, 2014). Despite considerable progress in the treatment and preventive measures regarding the disease, the number of cases has not decreased significantly and its control is still a challenge (Harhay et al., 2011; Dantas-Torres et al., 2012). This situation has been correlated with the existence of other reservoir hosts responsible for the maintenance of the protozoan in the domestic and peridomestic habitat (Maia and Campino 2011). When considering the growing number of reports and studies that reveal a high prevalence of natural infection of domestic cats by *Leishmania* sp., mostly in Brazil (Chatzis et al., 2014; Metzendorf

et al., 2017; Madruga et al., 2018; Pennisi and Persichetti, 2018; Brianti et al., 2019, Headley et al., 2019; Rocha et al., 2019); it is believed that this species can play a significant role in the transmission cycle of the parasite (Maroli et al., 2007; Maia and Campino, 2011).

Regarding the distribution of the disease in cats, studies have certified that their infection by *Leishmania* sp. has been relatively frequent in endemic regions for canine visceral leishmaniasis (CVL) (Costa et al., 2010; Vides et al., 2011; Lombardo et al., 2012; Oliveira et al., 2015, Metzdorf et al., 2017). However, the city of Patos, in the inland portion of the state of Paraíba, is an endemic area for CVL (Porto 2010; Silva et al., 2016) and there is only one study (Silva et al., 2018) regarding the prevalence of feline leishmaniasis by evaluating the presence of anti-*Leishmania* sp. antibodies.

Different techniques can confirm the diagnosis of leishmaniasis, namely cytology, histopathology, serology, immunohistochemistry, and PCR (Asfaram et al., 2019). In Brazil, epidemiological studies that have investigated the infection of cats by *Leishmania* sp. by detecting anti-*Leishmania* sp. (ELISA and IFAT) were considerably more numerous (Vides et al., 2011; Sobrinho et al., 2012, Silva et al., 2013; Sousa et al., 2014; Silva et al., 2018) when compared to those by parasitic DNA (Oliveira et al., 2015; Benassi et al., 2017; Metzdorf et al., 2017) and by the identification of antigens through antibodies associated with markers (Vides et al., 2011). Still, few of those who used the PCR have evaluated more than one type of tissue and/or fluid, or used more than one diagnostic technique.

In dogs, studies have evaluated tissue and/or ocular fluid samples for the diagnosis of leishmaniasis, considering the clinical findings of ocular alterations in that species (Berrahal et al., 1996; Brito et al., 2006). Likewise, some authors have reported the high prevalence of ophthalmic alterations in felines with leishmaniasis (Pennisi et al., 2004; Leiva et al., 2005; Verneuil, 2013); however, more accurate investigations of ocular specimens from cats are needed. Because of this, this study aimed to investigate the feasibility of using conjunctival fragments to detect infection by *Leishmania* sp. in cats from an endemic region, using different diagnostic techniques.

## **2. Materials and methods**

### *2.1. Animals*

The collections were conducted in 16 domestic cats (10 males and six females, over one year of age) submitted to elective surgical procedures at the Hospital Veterinário Universitário Prof. Dr. Ivon Macêdo Tabosa, from the Federal University of Campina Grande (UFCG). Of the total number of animals, 10 have shown some clinical ophthalmic, dermatological, and/or systemic signs. All animals were selected due to accessibility and the possibility of collecting the materials, which was conducted with prior clarification and consent from their guardians, or protectors, through an authorization term.

### *2.2. Clinical evaluation*

On physical examination, attention was mainly given to the presence of clinical signs compatible with leishmaniasis, namely systemic (fever, lethargy, weight loss, stomatitis, dehydration, vomiting, jaundice, diarrhea, polyuria, polydipsia, localized or generalized lymphadenomegaly, hepatomegaly, and splenomegaly), ophthalmic (uveitis, conjunctivitis, blepharitis, corneal ulceration, keratitis, and glaucoma), and dermatological (erythema, alopecia, papules, pustules, ulcers and/or ulcerated nodules and hard-to-heal wounds) changes. These signs, when present, as well as those not mentioned, were marked and added to the clinical record.

### *2.3. Collection of biological samples*

Using the general anesthesia for surgical procedures, the following collections were performed: skin cytology (in the presence of lesions), puncture of the right popliteal lymph node, peripheral blood collection, cytology, and biopsy of the lower eyelid conjunctiva from both eyes.

Through medial saphenous, cephalic, or jugular veins venipuncture, 1 ml of whole blood was collected. After, the blood was transferred to sterile microtubes containing anticoagulant - ethylenediaminetetraacetic acid (EDTA) - and then stored at -20° C until the moment of processing for molecular analysis at the Laboratory of Parasitic Diseases from the Federal Rural University of Pernambuco (UFRPE).

To collect the skin samples, a sterile cytological brush (Kolplast, São Paulo, Brazil) was rubbed over the skin areas of the injured animals. The samples were distributed on glass slides, which were dried at room temperature and then fixed in a 0.1% (w/v) triarylmethane solution for further staining and cytological analysis.

For the collection of conjunctival samples, anesthetic eye drops, based on 0.5% (w/v) proxymetacaine hydrochloride, were instilled (Anestalcon®, Alcon Laboratórios do Brasil, São Paulo, Brazil) and, after a few minutes, with the aid of a sterile cytological brush (Kolplast, São Paulo, Brazil), the material was collected by careful exfoliation of the inferior conjunctival fornix from both eyes. The samples were distributed on glass slides, which were dried at room temperature and then fixed in a 0.1% (w/v) triarylmethane solution for further staining and cytological analysis.

Then, two fragments of 0.3 x 0.2 x 0.1 cm were removed from the inferior palpebral conjunctiva of each eye, with the aid of Iris scissors and conjunctival forceps. After, a thin layer of ointment based on tobramycin and dexamethasone (Tobradex®, Alcon Laboratórios do Brasil LTDA, São Paulo, SP, Brazil) was applied to the lower eyelid conjunctiva of both eyes. One of the fragments was packaged and fixed in 10% buffered formalin (w/v), cleaved, and sent for processing and histopathological analysis (research for amastigote forms of *Leishmania* sp.) at the Animal Pathology Laboratory at UFCG; the other was inserted into a sterile microtube (0.5 ml), containing a 0.9% (w/v) NaCl solution, and stored at -20°C, until the moment of processing for molecular analysis in the Laboratory of Parasitic Diseases at UFRPE.

Two punctures from the right lymph node, for aspiration, were performed using a 40 x 1.2 mm (mm) hypodermic needle and a syringe (10 ml). An aspirated sample was inserted into a sterile microtube (0.5 ml), containing a 0.9% (w/v) NaCl solution, and stored at -20°C until the moment of processing for molecular analysis. The other sample obtained was applied on glass slides and, with the aid of an extender blade, a squash was prepared using the squash technique, which was then fixed in a 0.1% (w/v) triarylmethane solution for further staining and cytological examination.

#### 2.4. Cytological analysis

The slides with lymph node smears and skin and conjunctival *swabs* were stained by the Rapid Panoptic method and subsequently evaluated by direct immersion microscopy (100x) to search for amastigote forms of *Leishmania* sp.

#### 2.5. Histopathological analysis

The conjunctival fragments underwent serial dehydration with increasing concentrations of alcohol (70% - 100%), diaphanization, and paraffin embedding, and were subsequently cut into sections from 4 to 5  $\mu\text{m}$ . Then, the slides were made, routinely stained with hematoxylin and eosin (HE), and analyzed under a microscope (40x) to search for amastigote forms of *Leishmania* sp.

#### 2.6. DNA extraction

For the DNA extraction from whole blood samples, the commercial kit ReliaPrep™ Blood gDNA Miniprep System (Promega, Madison, USA) was used and, for conjunctival fragments and lymph node samples, the ReliaPrep™ gDna Tissue Miniprep System (Promega, Madison, USA), according to the instructions from the manufacturer.

#### 2.7. Polymerase Chain Reaction (PCR)

For each sample, a mixture composed of 2.5  $\mu\text{l}$  of DNA was prepared; 6.25  $\mu\text{l}$  of Master Mix (GoTaq® Green Master Mix, Promega, USA), 0.5  $\mu\text{l}$  of each Primer (5 pmol/ $\mu\text{l}$ ) and 2.75  $\mu\text{l}$  of ultrapure water, totaling 12.5  $\mu\text{l}$  of final volume. The oligonucleotide primers used were the MC1 (5'-GTTAGCCGATGGTGGTCTTG-3') and MC2 (5'-CACCCATTTTCCGATTTTG-3'), which enable 447-base-pair amplification (Cortes et al., 2004). All amplifications included a negative control, in which ultrapure water was added to replace the DNA, and positive control, with 2.5  $\mu\text{l}$  of DNA extracted from a lymph node sample from a dog naturally infected with *L. infantum*. PCR amplification was performed in a thermocycler (Line Gene 9660®, Bioer, Hangzhou, China) under the following conditions: initial denaturation step at 94 °C for 2 minutes, followed by 30 cycles of denaturation at 94 °C for 20 seconds, annealing at 57 °C for 20 seconds, and extension at 72 °C for 30 seconds, ending with a 5 min extension at 72 °C.

The PCR amplification products were subjected to analysis by electrophoresis on a 2% agarose gel (UltraPure™ Agarose, Invitrogen™, USA) in a Tris-Acetate-EDTA buffer (TAE 50X® Buffer, LGC Biotechnology, SP, Brazil) to 100V and 300mA for 60 minutes. Five µl of the sample was applied to the gel – stained with 0.5 µl of Blue Green Loading Dye I® (LGC Biotechnology, São Paulo, Brazil) – and 3 µl of a 100pb molecular marker (GeneDireX®, Taiwan, Taiwan, China). Subsequently, the gels were visualized and analyzed in an ultraviolet transilluminator, coupled to a computer with imaging software.

### 2.8. Immunohistochemistry

The conjunctival samples for immunohistochemistry were processed according to the methodology described by Tafuri et al. (2004). In summary, a heterologous hyperimmune serum from a dog naturally infected with *L. infantum* (positive results in the parasitological test of the bone marrow and antibody immunofluorescence titer test \$ 40), diluted at 1:100 (in phosphate-buffered saline 0.01 M), was used as the primary antibody. As a detection system, commercially available streptavidin-peroxidase complex (LSAB + kit, Dako, Carpinteria, California, USA) was used. Reactions were developed with a solution of 3,3'-diaminobenzidine. Finally, the slides were counterstained with Harris hematoxylin, dehydrated, clarified with xylene, mounted with Entellan® new, and analyzed with a light microscope.

## 3. Results

Histopathological analysis of the conjunctiva and cytological analysis of the skin, conjunctiva, and lymph node did not reveal the presence of amastigote forms of *Leishmania* sp.

Of the 16 animals evaluated, four (4/16 – 25%) tested positive both in the PCR and IHC techniques (Table 1).

In the PCR, eight positive samples for *Leishmania infantum* were found, corresponding to five cats, out of the 16 tested (5/16 – 31.25%). Of the eight positive samples, seven (7/8 – 87.5%) were related to conjunctival fragments; and one (1/8 - 12.5%) belonging to whole blood.



Of the five animals mentioned above, two (2/5) were positive from samples of conjunctival fragments from both eyes; two (2/5), from a conjunctival fragment from a single eye, and the other (1/5) from a sample of whole blood and a conjunctival fragment from a single eye (Table 1).

Systemic clinical, ophthalmic, and dermatological signs were found in four (4/5) PCR positive animals; of these, one (1/4) had a pustular lesion in the chin region and ocular secretion in the right eye; one (1/4) had gingivitis, popliteal lymphadenomegaly, blepharitis and conjunctival hyperemia in both eyes; one (1/4) had only anterior synechia in the lower paraxial region of the left eye, and the other (1/4) had gingivitis and diarrhea. Only one of the PCR-positive animals (1/5) had no clinical signs (Table 1).

The immunohistochemical assay of 31 conjunctival samples allowed the identification of 17 positive ones, concerning 13 animals (13/16 – 81.25%); of these, five (5/13) were positive from samples from both eyes and eight (8/13) from samples from a single eye (Table 1).

Of the 13 IHC-positive animals, eight had clinical signs and/or concomitant diseases, 1/8 had only gingivitis; 1/8 squamous cell carcinoma in both ears, right popliteal lymphadenomegaly; 1/8 bilateral lymphadenomegaly (popliteal) and generalized hairy rarefaction (hypotrichosis); 1/8 hypotrichosis in the cervical region, pediculosis and verminosis; 1/8 nasal discharge; (1/8) gingivitis, lymphadenomegaly, blepharitis, and conjunctival hyperemia; (1/8) had only anterior synechia; (1/8) gingivitis and diarrhea (Table 1).

#### **4. Discussion**

Investigations on the occurrence of feline leishmaniasis have been using different samples and diagnostic methods consolidated in dogs; however, the results have been conflicting and vary greatly between the samples analyzed, and there is little information about the diagnostic value of different tissues, such as the conjunctiva, with the applicability of multiple techniques.

The conjunctiva is a structure rich in lymphoid tissue and has been identified as a good source of *Leishmania* sp. (Berrahal et al., 1996; Solano-Gallego et al., 2001; Leite et al., 2010; Oliveira et al., 2015; Costa-Val et al., 2020). In fact, in this study, the detection of *L. infantum*

by PCR occurred mainly from conjunctival fragments, corroborating what was found in a study with dogs, in which conjunctival biopsies using the same technique were also evaluated (Berrahal et al., 1996). In studies with cats, in which the conjunctiva swab to detect *Leishmania* sp. by PCR was used, the percentages were lower – 0.0% (Urbani et al., 2020) 1.85% (Benassi et al., 2017), 2.86% (Rocha et al., 2019), 3.1% (Chatzis et al., 2014), 6% (Metzdorf et al., 2017), 13.5% (Oliveira et al., 2015), 16.7% (Pennisi et al., 2012), and 23.1% (Marques et al., 2013) – than the one obtained in this research, which can be justified by the smaller amount of biological material from the swab sample concerning the conjunctival fragment.

Furthermore, it was possible to observe a higher percentage of PCR-positive cats from conjunctival fragments (5/16 – 31.25%) compared to whole blood samples (1/16 – 6.25%), in agreement with what was found in studies with cats (Pennisi et al., 2012; Marques et al., 2013; Benassi et al., 2017) and dogs (Lombardo et al., 2012), in which a higher percentage of PCR-positive animals, by conjunctival swab in relation to blood samples, was obtained. Other authors, when evaluating 233 (Spada et al., 2013) and 108 (Benassi et al., 2017) blood samples from cats by PCR, reported that none were positive for *Leishmania* sp., although some of them were positive in other tests, or some of the animals were positive in another type of sample. These results suggest that blood is possibly not a good biological sample to detect animals infected with *Leishmania* sp. by PCR, considering that amastigote forms are rarely seen in the bloodstream (Maia and Campino, 2011; Rivas et al. al., 2018). Despite being more invasive than peripheral blood collection and conjunctival swab, the conjunctival biopsy is not a complex technique and did not cause any change in the referred structure of the studied animals.

No lymph node sample was positive by PCR, although one of the animals that tested positive in another type of sample had reactive popliteal lymph node. Some authors found different percentages – 1.1% (Spada et al., 2016), 3% (Metzdorf et al., 2017), 4.4% (Spada et al., 2020), 11.7% (Pennisi et al., 2012), and 24.5% (Lombardo et al., 2012) – when detecting *L. infantum* in lymph node samples by PCR. Possible explanations for this would be the tropism of the *Leishmania* sp. strain; the specific immunity of each organ (Francino et al., 2006, Maia and Campino, 2008); the low amount of biological material from the lymph node aspirate, considering that collection is not always feasible due to the difficulty of identifying it, especially regarding cats; the parasite load is below the detection limit in that tissue, or

because of probable compartmentalization of the infection. Thus, the need to analyze, when possible, different tissues is highlighted to reduce the underestimation of the prevalence of infection (Chatzis et al., 2014).

In this study, amastigote forms of *Leishmania* sp. were not visualized by cytological evaluation of the conjunctiva, skin, and lymph nodes, although this analysis revealed satisfactory cellularity. Therefore, the result of this low sensitivity falls on the low parasite load of the aforementioned tissues and corroborates what was found by Chatzis et al. (2014), who obtained negative results in the cytological examination of all evaluated samples, thus defining the status of the infection of cats from PCR results, as reported here. These authors have concluded that, although cytology is a valuable technique in cases of suspected infection, it is not indicated as a sensitive diagnostic method in epidemiological studies. Different prevalence of cytological examination for the diagnosis of leishmaniasis in cats have been described (Bresciani et al., 2010; Costa et al., 2010; Vides et al., 2011) and, indeed, this technique has underestimated the real prevalence of the infection (Chatzis et al., 2014; Metzdorf et al., 2017).

In the histopathological analysis of the conjunctival fragments, amastigote forms of *Leishmania* sp. were not identified, as described in a work with dogs, in which the tissues of the eye bulb and its adnexa were evaluated (Fulgêncio, 2006). However, despite the low sensitivity of the histopathological examination (Bourdoiseau et al., 1997; Solano-Gallego et al., 2011), amastigote forms of *Leishmania* sp. have already been seen in ocular tissues of cats (Leiva, 2005; Navarro et al., 2010; Verneuil, 2013). Thus, the result obtained here is attributed to the low parasite load of the tissue investigated and the low sensitivity of the aforementioned technique which, although specific, presents difficulty in visualizing the parasites (Bourdoiseau et al., 1997), lacking complementary methods, such as the IHC (Bourdoiseau et al., 1997; Solano-Galego et al., 2011).

In the present study, the IHC for the detection of *Leishmania* sp. in the conjunctiva allowed the identification of 13/16 positive cats, of which 9/13 were confirmed only by this technique, which increased the percentage of positive results, corroborating previous descriptions in studies in cats (Navarro et al., 2010, Vides et al., 2011; Rivas et al., 2018) and dogs (Bourdoiseau et al., 1997; Xavier et al., 2006; Queiroz et al., 2010), in which this method increased the chances of detection of the parasites, although with little load in the tissues

examined. The IHC is referred to as a highly sensitive and specific technique for the diagnosis of leishmaniasis (Bourdoiseau et al., 1997; Vides et al., 2011; Rivas et al., 2018) and has attested to having greater sensitivity concerning histopathological evaluations, especially in tissues with a low parasite load (Maia and Campino, 2008; Navarro et al., 2010; Queiroz et al., 2010; Vides et al., 2011).

The clinical signs of systemic, ophthalmic, and dermatological diseases depicted here (Table 1) are in accordance with those described in studies with cats (Vides et al., 2011; Verneuil 2013; Chatzis et al., 2014; Metzdorf et al., 2017; Brianti et al., 2019; Fernandez-Gallego et al., 2020) and dogs that tested positive for leishmaniasis (Brito et al., 2006; Lombardo et al., 2012), adding the clinical manifestations of uveitis, glaucoma, keratitis, corneal ulcer and edema, chemosis, cataract, eyelid nodular lesion, stomatitis, vomiting, anorexia, alopecia, crusts, onychogryphosis, nasal mucopurulent discharge, and oral ulcers. Also, corroborating what was observed by other authors (Chatzis et al., 2014), the existence of the infection, confirmed by PCR, was related to at least one clinical sign compatible with leishmaniasis, although cats are considered resistant to the infection. All animals underwent preoperative examinations for elective surgery, and even in this situation it is not possible to certify that the clinical signs observed were associated solely with leishmaniasis, considering that the presence of other affections (respiratory and digestive diseases, dermatopathies, lymphoma, feline leukemia virus, feline immunodeficiency virus, periodontal disease, and feline infectious peritonitis), which can have the same clinical signs, warning of the need to include them in differential diagnoses, especially in endemic regions.

## **5. Conclusion**

In view of the findings, it is concluded that the conjunctival tissue has relevant diagnostic value for *Leishmania* sp. in cats and therefore its usefulness can be considered for analysis using the IHC and PCR. In addition, the results obtained highlight the need to employ multiple techniques to obtain the diagnosis, to increase the possibilities of positive results.

## **Ethics statement**

The study was approved by the Ethics Committee on the Use of Animals from the Federal University of Campina Grande (CEUA-UFCG) under protocol n° 076/2019 and conducted

following the human principles established in the ARVO Declaration (*Statement for the Use of Animals in Ophthalmic and Vision Research*) for the Use of Animals in Ophthalmological Research.

### **Funding**

This research did not receive any specific grant from funding agencies in the public, commercial, or not-for-profit sectors.

### **Declaration of competing interest**

The authors declare that there are no competing interests.

### **Acknowledgments**

The Coordenação de Aperfeiçoamento de Pessoal de Nível Superior (CAPES). The authors are immensely grateful to Professor Leucio Câmara Alves, PhD, coordinator of the laboratory of parasitic diseases at UFRPE, for enabling the processing and analysis of the samples.

### **References**

- Alvar, J., Vélez, I.D., Bern, C., Herrero, M., Desjeux, P., Cano, J., Jannin, J., den Boer M., 2012. Leishmaniasis worldwide and global estimates of its incidence. *PloS. One* 7, 35671. <https://doi.org/10.1371/journal.pone.0035671>
- Asfaram, S., Fakhar, M., Teshnizi, S.H., 2019. Is the cat an important reservoir host for visceral leishmaniasis? A systematic review with meta-analysis. *J. Venom. Anim. Toxins. incl Trop. Dis.* 25, e20190012. <https://doi.org/10.1590/1678-9199-JVATITD-2019-0012>
- Baneth, G., Koutinas, A.F., Solano-Gallego, L., Bourdeau, P., Ferrer L., 2008. Canine leishmaniosis - new concepts and insights on an expanding zoonosis: part one. *Trends. Parasitol.* 24(7), 324–330. <https://doi.org/10.1016/j.pt.2008.04.001>
- Benassi, J.C., Benvenga, G.U., Ferreira, H.L., Pereira, V.F., Keid, L.B., Soares, R., Oliveira T.M.F.S., 2017. Detection of *Leishmania infantum* DNA in conjunctival swabs of cats by quantitative real-time PCR. *Exp. Parasitol.* 177, 93–97. <https://doi.org/10.1016/j.exppara.2017.04.004>

- Bern, C., Maguire, J.H., Alvar, J., 2008. Complexities of assessing the disease burden attributable to leishmaniasis. *PLoS. Negl. Trop. Dis.* 2, e313. <https://doi.org/10.1371/journal.pntd.0000313>
- Berrahal, F., Mary, C., Roze, M., Berenger, A., Escoffier, K., Lamouroux, D., Dunan S., 1996. Canine leishmaniasis: identification of asymptomatic carriers by polymerase chain reaction and immunoblotting. *Am. J. Trop. Med. Hyg.* 55(3), 273–277. <https://doi.org/10.4269/ajtmh.1996.55.273>
- Bourdoiseau, G., Marchal, T., Magnol, J.P., 1997. Immunohistochemical detection of *Leishmania infantum* in formalin-fixed, paraffin-embedded sections of canine skin and lymph nodes. *J. Vet. Diag. Invest.* 9(4), 439–440. <https://doi.org/10.1177/104063879700900421>
- Bresciani, K.D.S., Serrano, A.C.M., de Matos, L.V.S., Savani, E.S.M., D’Auria, S.R.N., Perri, S.H.V., Bonello, F.L., Coelho, W.M.D., Aoki, C.G., Costa, A.J., 2010. Ocorrência de *Leishmania* spp. em felinos do município de Araçatuba, SP. *Rev Bras Parasitol Vet.* 19(2),127–129.
- Brianti, E., Celi, N., Napoli, E., Abbate, J.M., Arfuso, F., Gaglio, G., Iatta, R., Giannetto, S., Gramiccia, M., Otranto, D., 2019. Treatment and long-term follow-up of a cat with leishmaniosis. *Parasit. Vectors.* 12(121), 1–7. <https://doi.org/10.1186/s13071-019-3388-9>
- Brito, F.L.C., Alves, L.C., Maia, F.C.L., Santos, E.S.C., Laus, J.L., Meunier, I.M.J., 2006. Ocular alterations in dogs naturally infected by *Leishmania (Leishmania) chagasi*. *Arq. Bras. Med. Vet. Zootec.* 58(5), 768–775. <https://doi.org/10.1590/S0102-09352006000500011>
- Chatzis, M.K., Andreadou, M., Leontides, L., Kasabalis, D., Mylonakis, M., Koutinas, A.F., Rallis, T., Ikonopoulou, J., Saridomichelakis, M.N., 2014. Cytological and molecular detection of *Leishmania infantum* in different tissues of clinically normal and sick cats. *Vet. Parasitol.* 202(2-4), 217–225. <https://doi.org/10.1016/j.vetpar.2014.02.044>
- Cortes, S., Rolão, N., Ramada, J., Campino L. 2004. PCR as a rapid and sensitive tool in the diagnosis of human and canine leishmaniasis using *Leishmania donovani* s.l.-specific kinetoplastid primers. *T. Roy. Soc. Trop. Med. H.* 98(1):12-17. [https://doi.org/10.1016/s0035-9203\(03\)00002-6](https://doi.org/10.1016/s0035-9203(03)00002-6)

- Costa, T.A.C., Rossi, C.N., Laurenti, M.D., Gomes, A.A.D., Vides, J.P., Sobrinho, L.S.V., Marcondes, M., 2010. Ocorrência de leishmaniose em gatos de área endêmica para leishmaniose visceral. *Braz. J. Vet. Res. Anim. Sci.* 47(3), 213–217. <https://doi.org/10.11606/issn.1678-4456.bjvras.2010.26858>
- Costa-Val, A.P., Coura, F.M., Barbieri, J.M., Diniz, L., Sampaio, A., Reis, J.K.P., Bueno B.L., Gontijo C.M.F., 2020. Serological study of feline leishmaniasis and molecular detection of *Leishmania infantum* and *Leishmania braziliensis* in cats (*Felis catus*). *Braz. J. Vet. Parasitol.* 29(2), 1–12. <https://doi.org/10.1590/S1984-29612020023>
- Dantas-Torres, F., Solano-Gallego, L., Baneth, G., Ribeiro, V.M., de Paiva-Cavalcanti, M., Otranto, D., 2012. Canine leishmaniosis in the Old and New Worlds: unveiled similarities and differences. *Trends Parasitol.* 28(12), 531–538. <https://doi.org/10.1016/j.pt.2012.08.007>
- Fernandez-Gallego, A., Bernabe, L.F., Dalmau, A., Esteban-Saltiveri, D., Font, A., Leiva, M., Ortuñez-Navarro, A., Peña, M.T., Tabar, M.D., Real-Sampietro, L., Saló, F., Lloret, A., Bardagí, M., 2020. Feline leishmaniosis: diagnosis, treatment and outcome in 16 cats. *J. Fel. Med. Surg.* 22(10), 993–1007. <https://doi.org/10.1177/1098612X20902865>
- Francino, O., Altet, L., Sánchez-Robert, E., Rodriguez, A., Solano-Gallego, L., Alberola, J., Ferrer, L., Sánchez, A., Roura, X., 2006. Advantages of real-time PCR assay for diagnosis and monitoring of canine leishmaniosis. *Vet. Parasitol.* 137(3-4), 214–221. <https://doi.org/10.1016/j.vetpar.2006.01.011>
- Fulgêncio, G.O. 2006. Prevalência de oftalmopatias em cães naturalmente infectados com *Leishmania (Leishmania) chagasi* no município de belo horizonte – estudo clínico e histopatológico. Dissertação de Mestrado, Universidade Federal de Minas Gerais, Belo Horizonte. 48p.
- Gramiccia, M., 2011. Recen tadvances in leishmaniosis in pet animals: Epidemiology, diagnostics and anti-vectorial prophylaxis. *Vet. Parasitol.* 181(1), 23–30. <https://doi.org/10.1016/j.vetpar.2011.04.019>
- Harhay, M.O., Olliaro, P.L., Costa, D.L., Costa, C.H.N., 2011. Urban parasitology: visceral leishmaniasis in Brazil. *Trends Parasitol.* 27(9), 403–409. <https://doi.org/10.1016/j.pt.2011.04.001>

- Headley, S.A., Pimentel, L.A., Amorim, I.F.G., Amude, A.M., Viana, N.E., Muraro, L.S., Tafuri, W.L., Santos, M.D., 2019. Immunohistochemical characterization of cutaneous leishmaniasis in cats from Central-west Brazil. *Vet. Parasitol. Reg. Stud. Rep.* 17, 100290. <https://doi.org/10.1016/j.vprsr.2019.100290>
- Laison, R., Rangel, E.F., 2005. *Lutzomyia longipalpis* and the ecoepidemiology of American visceral leishmaniasis, with particular reference to Brazil - a review. *Mem. Inst. Oswaldo Cruz* 100(8),811–827. <https://doi.org/10.1590/S0074-02762005000800001>
- Leite, R.S., Ferreira, S.D., Ituassu, L.T., de Melo, M.N., de Andrade, A.S., 2010. PCR diagnosis of visceral leishmaniasis in asymptomatic dogs using conjunctival *swab* samples. *Vet. Parasitol.* 170, 201–206. <https://doi.org/10.1016/j.vetpar.2010.02.020>
- Leiva, M., Lloret, A., Peña, T., Roura, X., 2005. Therapy of ocular and visceral leishmaniasis in a cat. *Vet. Ophthalmol.* 8(1), 71–75. <https://doi.org/10.1111/j.1463-5224.2005.00342.x>.
- Lombardo, G., Pennisi, M.G., Lupo, T., Migliazzo, A., Capri, A., Solano-Gallego, L., 2012. Detection of *Leishmania infantum* DNA by real-timePCR in canine oral and conjunctival swabs and comparison with other diagnostic techniques. *Vet. Parasitol.* 184(1), 10–17. <https://doi.org/10.1016/j.vetpar.2011.08.010>
- Madruga, G., Ribeiro, A.P., Ruiz, T., Sousa, V.R.F., Campos, C.G., Almeida, A.B.P.F., Pescador, C.A., Dutra, V., 2018. Ocular manifestations of leishmaniasis in a cat: first case report from Brazil. *Arq. Bras. Med. Vet. Zootec.* 70(5), 1514–1520. <https://doi.org/10.1590/1678-4162-9244>
- Maia, C., Campino, L., 2011. A importância do gato doméstico (*Felis catus domesticus*) na epidemiologia da leishmaniose zoonótica. *Vet. Med.* 13(76), 46–49.
- Maia, C., Nunes, M., Campino, L., 2008. Importance of cats in zoonotic leishmaniasis in Portugal. *Vector Borne Zoonotic Dis.* 8(4), 555–559. <https://doi.org/10.1089/vbz.2007.0247>
- Maroli, M., Pennisi, M.G., Di Muccio, T., Khoury, C., Gradoni, L., Gramiccia, M., 2007. Infection of sandflies by a cat naturally infected with *Leishmania infantum*. *Vet. Parasitol.* 145(3-4), 357–360. <https://doi.org/10.1016/j.vetpar.2006.11.009>



- Marques, C.S., Santos, M.F., Pomba, C., Gomes, L., Duarte, A., Meireles, J., Tavares, L., Gomes, G.S., Fonseca, I.P., 2013. Detection of *Leishmania* infection in cats by qPCR of blood and conjunctival swabs and by indirect Immunofluorescence assay. Anais do Fifth World Congress on Leishmaniasis, Porto de Galinhas, PE, p. 242-243. (Resumo).
- Metzdorf, I.P., da Costa Lima, M.S.Jr., Matos, M.F.C., de Souza Filho, A.F., de Souza Tsujisaki, R.A., Franco, K.G., Shapiro, J.T., Borgesa, F.A., 2017. Molecular characterization of *Leishmania infantum* in domestic cats in a region of Brazil endemic for human and canine visceral leishmaniasis. Acta trop. 166,121–125. <https://doi.org/10.1016/j.actatropica.2016.11.013>
- Navarro, J.A., Sánchez, J., Peñafiel-Verdú, C., Buendía, A.J., Altimira, J., Vilafranca, M., 2010. Histopathological lesions in 15 cats with leishmaniosis. J. Comp. Pathol. 143(4), 297–302. <https://doi.org/10.1016/j.jcpa.2010.03.003>
- Noli, C., Saridomichelakis, M.N., 2014. Na update on the diagnosis and treatment of canine leishmaniosis caused by *Leishmania infantum* (syn. *L. chagasi*). Vet. J. 202(3), 425-435. <https://doi.org/10.1016/j.tvjl.2014.09.002>
- Oliveira, T.M., Pereira, V.F., Benvenga, G.U., Martin, M.F., Benassi, J.C., da Silva, D.T., Starke-Buzetti, W.A., 2015. Conjunctival swab PCR to detect *Leishmania* spp. in cats. Rev. Bras. Parasitol. Vet. 24(2), 220–222. <https://doi.org/10.1590/S1984-29612015016>
- Pennisi, M.G., Venza, M., Reale, S., Vitali, F., Giudice, S.L., 2004. Case report of leishmaniasis in four cats. Vet. Res. Commun. 28(1), 363–366. <https://doi.org/10.1023/b:verc.0000045447.96444.be>
- Pennisi, M.G., Lupo, T., Malara, D., Masucci, M., Migliazzo, A., Lombardo, G., 2012. Serological and molecular prevalence of *Leishmania infantum* infection in cats from southern Italy. J. Feline Med. Surg. 14, 656–657.
- Pennisi, M.G., Persichetti, M.F., 2018. Feline leishmaniosis: Is the cat a small dog? Vet. Parasitol. 251, 131–137. <https://doi.org/10.1016/j.vetpar.2018.01.012>
- Porto, M.L. 2010. Soroprevalência e fatores de risco para Leishmaniose Visceral Canina em Patos, Paraíba, Brasil. Trabalho de conclusão de curso, Universidade Federal de Campina Grande, Patos. 46 p.

- Queiroz, N.M.G.P., Assis, J., Oliveira, T.M.F.S., Machado, R.Z., Cárís, M., Nunes, C.M., Wilma, A., Starke-Buzetti, W.A., 2010. Diagnóstico da Leishmaniose Visceral Canina pelas técnicas de imunistoquímica e PCR em tecidos cutâneos em associação com a RIFI e ELISA-teste. *Rev. Bras. Parasitol. Vet.* 19(1), 32–38. <https://doi.org/10.4322/rbpv.01901006>
- Rivas, A.K., Alcover, M., Martínez-Orellana, P., Montserrat-Sangrà, S., Nachum-Biala, Y., Bardagí, M., Fisa, R., Riera, C., Baneth, G., Solano-Gallego, L., 2018. Clinical and diagnostic aspects of feline cutaneous leishmaniosis in Venezuela. *Parasit. Vectors.* 11(141), 1–7. <https://doi.org/10.1186/s13071-018-2747-2>
- Rocha, A.V.V.O., Moreno, B.F.S., Cabral, A.D., Louzeiro, N.M., Miranda, L.M., Santos, V.M.B., Costa, F.B., Nogueira, R.M.S., Marcili, A., Sperança, M.A., Costa, A.P., 2019. Diagnosis and epidemiology of *Leishmania infantum* in domestic cats in an endemic area of the Amazon region, Brazil. *Vet. Parasitol.* 273, 80–85. <https://doi.org/10.1016/j.vetpar.2019.08.007>
- Silva, R.B.S., Leite, D.P.S.B., Martins Filho, E., Silva, L.F.F., Braz, B.M.A., Melo, M.A., 2018. Anticorpos ANTI-*Leishmania* sp. em *Felis catus domesticus* atendidos no Hospital Veterinário da UFCG, Patos-PB. Anais do 54º Congresso da Sociedade Brasileira de Medicina Tropical, Olinda, PE, p. 113–1114.
- Silva, R.B.S., Mendes, R.S., Santana, V.L., Souza, H.C., Ramos, C.P.S., Souza, A.P., Andrade, P.P., Melo, M.A., 2016. Aspectos epidemiológicos da leishmaniose visceral canina na zona rural do semiárido paraibano e análise de técnicas de diagnóstico. *Pesq. Vet. Bras.* 36(7), 625–629. <https://doi.org/10.1590/S0100-736X2016000700011>
- Silva, R.C., Ramos, R.A., Pimentel, D.S., Oliveira, G.M., Carvalho, G.A., Santana, M.D., Faustino, M.A.G., Alves, L.C., 2013. Detection of antibodies against *Leishmania infantum* in cats (*Felis catus*) from the State of Pernambuco, Brazil. *Rev Soc Bras Med Trop.* 47(1), 108–109. <https://doi.org/10.1590/0037-8682-0005-2012>
- Sobrinho, L.S., Rossi, C.N., Vides, J.P., Braga, E.T., Gomes, A.A., de Lima, V.M., Perri, S.H., Generoso, D., Langoni, H., Leutenegger, C., Biondo, A.W., Laurenti, M.D., Marcondes M., 2012. Coinfection of *Leishmania chagasi* with *Toxoplasma gondii*. Feline Immunodeficiency Virus (FIV) and Feline Leukemia Virus (FeLV) in cats from an

- endemic area of zoonotic visceral leishmaniasis. *Vet. Parasitol.* 187(1-2), 302–306. <https://doi.org/10.1016/j.vetpar.2012.01.010>
- Solano-Gallego, L., Miró, G., Koutinas, A., Cardoso, L., Pennisi, M.G., Ferrer, L., Bourdeau, P., Oliva, G., Baneth, G., 2011. LeishVet guidelines for the practical management of canine leishmaniasis. *Parasit. Vectors.* 4(86), 1–16. <https://doi.org/10.1186/1756-3305-4-86>
- Solano-Gallego, L., Morell, P., Arboix, M., Alberola, J., Ferrer, L., 2001. Prevalence of *Leishmania infantum* infection in dogs living in an area of canine leishmaniasis endemicity using PCR on several tissues and serology. *J. Clin. Microbiol.* 39(2), 560–563. <https://doi.org/10.1128/JCM.39.2.560-563.2001>
- Sousa, K.C., Herrera, H.M., Domingos, I.H., Campos, J.B., Santos, I.M., Neves, H.H., Machado, R.Z., André, M.R., 2014. Serological detection of *Toxoplasma gondii*, *Leishmania infantum* and *Neospora caninum* in cats from an area endemic for leishmaniasis in Brazil. *Ver. Bras. Parasitol. Vet.* 23(4), 449–55. <https://doi.org/10.1590/S1984-29612014078>
- Spada, E., Proverbio, D., Migliazzo, A., Della Pepa, A., Perego, R., Bagnagatti De Giorgi, G., 2013. Serological and Molecular Evaluation of *Leishmania infantum* Infection in Stray Cats in a Nonendemic Area in Northern Italy. *ISRN Parasitol.* 2013, 1–6. <https://doi.org/10.5402/2013/916376>
- Spada, E., Canzi, I., Baggiani, L., Perego, R., Vitale, F., Migliazzo, A., Proverbio, D., 2016. Prevalence of *Leishmania infantum* and co-infections in stray cats in northern Italy. *Comp. Immunol. Microbiol. Infect. Dis.* 45, 53–58. <https://doi.org/10.1016/j.cimid.2016.03.001>
- Spada, E., Perego, R., Vitale, F., Bruno, F., Castelli, G., Tarantola, G., Baggiani, L., Magistrelli, S., Proverbio, D., 2020. Feline *Leishmania* spp. Infection in a Non-Endemic Area of Northern Italy. *Animals* 10(5), 817. <https://doi.org/10.3390/ani10050817>
- Tafuri, W.L., Santos, R.L., Arantes, R.M., Gonçalves, R., Melo, M.N., Michalick, M.S.M., Tafuri, W.L., 2004. An alternative immunohistochemical method for detecting *Leishmania* amastigotes in paraffin-embedded canine tissues. *J. Immunol. Methods*, 292, 17–23. <https://doi.org/10.1016/j.jim.2004.05.009>

- Urbani, L., Tirolo, A., Salvatore, D., Tumbarello, M., Segatore, S., Battilani, M., Balboni, A., Dondi, F., 2020. Serological, molecular and clinicopathological findings associated with *Leishmania infantum* infection in cats in Northern Italy J. Feline Med. Surg. 22(10), 935–943. <https://doi.org/10.1177/1098612X19895067>
- Verneuil, M., 2013. Leishmaniose oculaire féline: à propos d'un cas. J. Fr. Ophtalmol. 36(4), 67-72. <https://doi.org/10.1016/j.jfo.2012.09.006>
- Vides, J.P., Schawardt, T.F., Sobrinho, L.S.V., Marinho, M., Laurenti, M.D., Biondo, A.W., 2011. *Leishmania chagasi* infection in cats with dermatologic lesions from an endemic area of visceral leishmaniasis in Brazil. Vet. Parasitol. 178(1-2), 22–28. <https://doi.org/10.1016/j.vetpar.2010.12.042>
- Xavier, S.C., Andrade, H.M, Monte, S.J.H., Chiarelli, I.M., Lima, W.G., Michalick, M.S.M., Tafuri, W.L., Tafuri, W.L., 2006. Comparison of paraffinembedded skin biopsies from different anatomical regions as sampling methods for detecting *Leishmania* infection in dogs using histological, immunohistochemical and PCR methods. BMC Vet. Res. 2(1), 17. <https://doi.org/10.1186/1746-6148-2-17>

**Table 1**

Distribution of PCR and IHC results in the detection of *Leishmania* sp., with their respective samples analyzed and clinical signs and/or concomitant diseases identified in 16 domestic cats in the municipality of Patos, Paraíba, Brazil.

Animal	PCR			IHC	Clinical signs/ concomitant diseases
	CJ	LF	WB		
A1	–	–	–	+ OS	Absent
A2	+ OD	–	–	–	Secretion (OD) and pustular lesion in the chin region
A3	–	–	–	+ OD	Gingivitis
A4	–	–	–	–	Notohedral mange
A5	+ OS	–	–	+ OS	Absent
A6	–	–	–	+ OU	Absent
A7	–	–	–	+ OU	Absent
A8	–	–	–	+ OD	SCC in both ear pinna and right popliteal lymphadenomegaly
A9	–	–	–	+ OD	Bilateral lymphadenomegaly (poplites) and generalized hypotrichosis
A10	–	–	–	–	Absent
A11	–	–	–	+ OU	Hypotrichosis in the cervical region, pediculosis and verminosis
A12	+ OS	–	+	+ OD	Anterior synechia (OS)
A13	+ OU	–	–	+ OD	Gingivitis, bilateral lymphadenomegaly (poplites), blepharitis and conjunctival

---

					hyperemia (OU)
A14	+ OU	N/S	-	+ OU	Gingivitis and diarrhea
A15	-	-	-	+ OU	Nasal discharge
A16	-	-	-	+ OS	Absent

---

OD (*oculus dexter*) = right eye, OS (*oculus sinister*) = left eye, OU (*oculus uterque*) = both eyes, CJ = conjunctiva, LF = lymph node, WB = whole blood, PCR = Polymerase Chain Reaction, IHC = Immunohistochemistry, ( + ) = positive, ( - ) = negative, N/S = (no sample).

## **CAPÍTULO II:**

### **Caracterização celular conjuntival e determinação de valores referenciais para os testes oftálmicos em caprinos Moxotó**

Artigo submetido à revista Ciência Rural - Qualis A3

**Characterization of conjunctival cells and determination of reference values for  
ophthalmic tests in Moxotó goats**

**Caracterização celular conjuntival e determinação de valores referenciais para os testes  
oftálmicos em caprinos Moxotó**

Karla Priscila Garrido Bezerra<sup>1\*</sup> Aline de Sousa Alves<sup>1</sup> Thiago da Silva Brandão<sup>1</sup> Arthur  
Willian de Lima Brasil<sup>2</sup> Agrício Moreira Dantas Neto<sup>3</sup> Raquel Guedes Ximenes<sup>1</sup> Jefferson  
da Silva Ferreira<sup>1</sup> Ivya Carmem Talieri<sup>4</sup> Almir Pereira de Souza<sup>1</sup>

**ABSTRACT**

This study aimed at standardizing reference values for the Schirmer's Tear Test (STT) and Intraocular Pressure (IOP), as well as to describe the cellularity of the ocular conjunctiva of healthy eyes, from goats of the Moxotó breed and the interference of age in such parameters. Thirty adult Moxotó goats (GA) and 10 healthy young goats (GJ) were selected and evaluated. The animals were submitted to STT; measurement of the IOP; and conjunctival swab for the cytological analysis. The average value obtained in the STT for the GA was  $11.65 \pm 3.16$  mm/min and  $9.90 \pm 2.97$  mm/min for the GJ. There was no significant difference in the average values of the STT between males and females (GA,  $P = 0.507$ ; GJ,  $P = 0.385$ ), right and left eyes (GA,  $P = 0.069$ ; GJ,  $P = 0.852$ ) or body weight ( $P = 0.631$ ). However, there was a significant difference between the values of the GA and the GJ ( $P = 0.033$ ). The average of the IOP was  $11.18 \pm 2.54$  mmHg in the first and  $10.10 \pm 2.40$  mmHg in the latter. There was no significant difference of the averages of the IOP obtained between the GJ and the GA ( $P = 0.098$ ), between genders (GA,  $P = 0.958$ ; GJ,  $P = 0.247$ ), right and left eyes (GA,  $P = 0.425$ ; GJ,  $P = 0.642$ ) or body weight ( $P = 0.117$ ). The conjunctival cytological samples disposed of numerous cellularity, revealing the same cellular pattern between young and adult goats. A predominance of superficial epithelial cells was observed and, in decreasing order of predominance, the presence of intermediate epithelial, squamous, basal, and caliciform cells. In addition, a variable quantity of lymphocytes and rare neutrophils was found. It is concluded that, from the analyzed data, the age of the Moxotó goats must be taken into consideration

<sup>1</sup> Programa de Pós-Graduação em Ciência e Saúde Animal, Universidade Federal de Campina Grande, Centro do Saúde e Tecnologia Rural, Avenida Universitária, s/n - Santa Cecília, Patos, PB, 58708-110, Brasil.

\*Corresponding author: [priscilagarridomv@gmail.com](mailto:priscilagarridomv@gmail.com)

<sup>2</sup> Departamento de Morfologia, Universidade Federal da Paraíba (UFPB), Jardim Universitário, s/n - Campus I - Castelo Branco, João Pessoa, PB, 58051-900, Brasil.

<sup>3</sup> Médico Veterinário autônomo, Natal, Rio Grande do Norte, Brasil.

<sup>4</sup> Departamento de Medicina Veterinária, UFPB, Campus II, Areia, Paraíba, Brasil.



when evaluating their tear production, as well as include the determination of the IOP in the ophthalmic examination of these animals.

**Key words:** tonometry, Schirmer's tear test, small ruminant, cytology, conjunctiva, diagnosis

## RESUMO

Objetivou-se, com este estudo, padronizar os valores referenciais para o teste lacrimal de Schirmer (TLS) e pressão intraocular (PIO), bem como descrever a celularidade da conjuntiva ocular de olhos sadios de caprinos da raça Moxotó e a interferência da idade nestes parâmetros. Foram selecionados e avaliados 30 caprinos Moxotó adultos (GA) e 10 caprinos jovens (GJ) sadios. Os animais foram submetidos a seguinte ordem de coleta de dados e amostras: TLS, aferição da PIO e *swab* conjuntival para análise citológica. O valor médio obtido no TLS no GA foi de  $11,65 \pm 3,16$  mm/min e  $9,90 \pm 2,97$  mm/min no GJ. Não houve diferença significativa nos valores médios do TLS entre machos e fêmeas (GA,  $P = 0,507$ ; GJ,  $P = 0,385$ ), entre os olhos direito e esquerdo (GA,  $P = 0,069$ ; GJ,  $P = 0,852$ ) ou em relação ao peso corporal ( $P = 0,631$ ), contudo, houve diferença significativa entre os valores do GJ e GA ( $P = 0,033$ ). A média da PIO foi de  $11,18 \pm 2,54$  mmHg no GA e  $10,10 \pm 2,40$  mmHg no GJ. Não houve diferença significativa das médias obtidas entre GA e GJ ( $P = 0,098$ ), entre os sexos (GA,  $P = 0,958$ ; GJ,  $P = 0,247$ ), entre os olhos direito e esquerdo (GA,  $P = 0,425$ ; GJ,  $P = 0,642$ ) ou em relação ao peso corporal ( $P = 0,117$ ). As amostras citológicas conjuntivais dispuseram de numerosa celularidade, revelando o mesmo padrão celular entre os caprinos jovens e adultos. Observou-se uma predominância de células epiteliais superficiais e, em ordem decrescente de predomínio, as células epiteliais intermediárias, as escamosas, as basais e as caliciformes. Ainda, constatou-se uma quantidade variável de linfócitos e raros neutrófilos. Conclui-se que o valor médio do TLS em caprinos Moxotó adultos, acima de um ano de idade, é significativamente maior do que o de jovens com quatro meses de idade, fato que deve ser levado em consideração ao avaliar este parâmetro na referida espécie. Ademais, a descrição da celularidade conjuntival e a determinação dos valores referenciais para o TLS e PIO aqui estabelecidos poderão contribuir para a consecução do diagnóstico e do tratamento de afecções oculares em caprinos Moxotó.

**Palavras-chave:** tonometria, teste lacrimal de Schirmer, pequeno ruminante, citologia, conjuntiva, diagnóstico

## INTRODUCTION

Goat farming is a valuable source of income for producers due to the sale of meat, skin, and milk. Brazil has one of the largest goat herds in the world, with more than 90% of it in the Northeast region (IBGE 2018), encompassing mixed-bred animals, exotic breeds, and native breeds, such as the Moxotó (OLIVEIRA, 2004). This breed is considered the oldest in Brazil, and the best choice for several producers, as it adapts to adverse environmental conditions, such as drought and sparse vegetation. Even with its cultural and economic value, and the ease of adapting to hostile environments, the Moxotó breed is among the native goat breeds that are threatened due to excessive crossbreeding with exotic ones (SANTOS et al., 2013). This situation has motivated the development of research aimed at conservation programs to protect their genetics.

The presence of this breed in institutions linked to programs for the conservation of goat genetic resources becomes an opportunity to conduct studies for obtaining data and providing information on the physiology of various systems, as well as the identification of experimental models for comparative studies.

Goats present relevant ocular diseases, which advance to discomfort, eating impairment, and temporary blindness, resulting in reduced milk production or of the corporal condition, generating relevant economic losses. Furthermore, the Moxotó goats are rustic and adapted to the extensive livestock production system (SOUZA *et al.*, 2015), which permits the movement of the animals over wide areas of the *caatinga* vegetation. This non-supervised lifestyle collaborates to the increase of eventual ocular lesions, which are not diagnosed, nor treated conveniently, due to the gaps in the ophthalmic knowledge, predominantly regarding basic reference data. This conjuncture has emphasized the need for developing descriptive studies concerning reference values, from this species, for basic routine ophthalmic tests. Among these, the Schirmer's tear test (STT), the measurement of the intraocular pressure (IOP), and the conjunctival cytology are highlighted due to their clinical applicability.

The tear film is responsible for the preservation of the health and normal functioning of the cornea and conjunctiva (OFRI *et al.*, 2002). Therefore, a deficit in tear production, found by Schirmer's tear test (STT), may result in alterations of the ocular structures previously mentioned (OFRI *et al.*, 2002; MONTIANI-FERREIRA *et al.*, 2008). The IOP, maintained predominantly by the balance between the production and drainage of the aqueous humor (MCLELLAN & MILLER, 2011), can be indirectly measured by tonometry. In veterinary medicine, the applanation method is one of the most commonly employed for this, contributing to the diagnosis and monitoring of ophthalmic affections of great relevance,

namely glaucoma, and uveitis (PIGATTO *et al.*, 2011). The conjunctival cytology is a valuable tool for diagnosing conjunctival alterations (LIMA *et al.*, 2010), as it enables the recognition of the inflammatory response to several noxae, as well as the detection of infectious agents and cells of neoplastic origin (WILLS *et al.*, 1997), contributing to the therapeutic guidance of the ocular affections.

To perform these tests, it is necessary to know the normality parameters. However, studies on the standardization of reference values for these tests, and which describe the normal cellularity of the ocular conjunctiva in goats, are still incipient. Therefore, this study aimed at standardizing such values for the STT and IOP, as well as to describe the cellularity of the ocular conjunctiva of healthy eyes from Moxotó goats, and the interference of age in these parameters.

## MATERIAL AND METHODS

*Animals.* Thirty adult Moxotó goats (20 females and 10 males) with bodyweight ranging from 15 kg to 47 kg (mean  $26.91 \pm 5.99$  kg), and ten young ones (five females and five males) weighing from 7kg to 9.5 kg (average of  $8.2 \pm 0.83$  kg), healthy, at the Goat Farming Sector from Fazenda NUPEÁRIDO (Núcleo de Pesquisa para o Desenvolvimento do Trópico Semi-Árido) from the Federal University of Campina Grande, Campus in Patos, Paraíba, were selected and evaluated. All four-month-old animals were included in the young animals group (GJ), and those with one year of age or more were included in the adult group (GA).

The collection of data and samples took place in the morning, in their shelter, where they were physically restrained, manually, in a quadrupedal position, by the veterinarian and caretakers responsible for the sector and their daily handling, respectively. The routine physical examination was performed in all the animals and, after that, the ophthalmic examination, with the intention of pre-selecting the ones that did not present clinical signs of systemic and/or ocular diseases. This included the evaluation of the neuro-ophthalmic reflexes, direct light exam, and both the eyes and periocular regions were inspected, in normal light, and with a light head magnifying glass, in search of macroscopic alterations.

After selection, the animals were submitted to the following order of data and sample collection: **1)** Schirmer's tear test; **2)** measurement of the intraocular pressure; **3)** conjunctival swab for cytological analysis. At the end of the collections, the fluorescein eye stain test was performed to exclude the presence of a corneal ulcer. To avoid discrepancies in the results, all tests were performed by the same researcher.

*Schirmer's tear test-1 (STT-1)*. The STT was conducted before the other analyses so that the tear production would not be influenced by eye drops, nor by the clinical procedures. The aqueous portion of the tear film was measured using strips of standardized and graduated (in millimeters) sterile absorbent paper of the STT (Schirmer Test<sup>®</sup>, Drogavet, João Pessoa, PB, Brazil), which were inserted in the inferior conjunctival fornix from both eyes, where they remained for 60 seconds and, immediately after this interval, the humid portion was measured (mm/min).

*Intraocular pressure (IOP)*. The IOP from both eyes was measured with a portable applanation tonometer (Tono-Pen Vet<sup>®</sup>, Reichert Technologies, NY, EUA) five minutes after the instillation of 0.5% proxymetacaine hydrochloride anesthetic eye drops (Anestalcon<sup>®</sup>, Alcon Laboratórios do Brasil, São Paulo, Brazil). The final result was registered in mmHg (average value obtained by the device) of the first successful reading, with a maximum standard deviation of 5% for each eye.

*Conjunctival cytology*. Making use of the topical anesthesia used in the IOP test, samples of the conjunctiva were collected using a sterile cytological brush (Kolplast, São Paulo, Brazil), by the careful exfoliation of the inferior conjunctival fornix from both eyes. Subsequently, the samples were distributed in glass slides, dried at room temperature, stained by the rapid panoptic method, and evaluated by optical direct microscopy, under 40 X and 100 X magnification.

*Statistical analysis*. The data were evaluated for their normality using the Shapiro-Wilk test and, those which presented normal distribution, were submitted to the T-test for independent or dependent samples; and the non-normal ones were evaluated by the Mann-Whitney or Wilcoxon Rank Sum tests. A simple linear regression was also applied to verify if the variable weight (dependent) interfered in the variables IOP and Schirmer (independent). The analyses were performed using the SPSS 23 software at a significance level of 5%.

## RESULTS

### *Schirmer's tear test -1 (STT-1)*

The average value obtained in the STT for the GA was  $11.65 \pm 3.16$  mm/min and  $9.90 \pm 2.97$  mm/min in the GJ (Table 1). There was no significant difference in the average values of the STT between males and females (GA,  $P = 0.507$ ; GJ,  $P = 0.385$ ), between the right and left eyes (GA,  $P = 0.069$ ; GJ,  $P = 0.852$ ) or concerning body weight ( $P = 0.631$ ). However, there was a significant difference between the average values of GA and GJ ( $P = 0.033$ ). In

addition, there was no significant difference in the values of the STT for the right eye between GA and GJ ( $P = 0.086$ ); neither for the left eye, between both groups ( $P = 0.210$ ).

#### *Intraocular pressure (IOP)*

The average of the IOP was  $11.18 \pm 2.54$  mmHg for the GA and  $10.10 \pm 2.40$  mmHg for the GJ (Table 1). There was no significant difference of the averages obtained between the GA and GJ ( $P = 0.098$ ), between genders (GA,  $P = 0.958$ ; GJ,  $P = 0.247$ ), between the right and left eyes (GA,  $P = 0.425$ ; GJ,  $P = 0.642$ ) or body weight ( $P=0.117$ ). Furthermore, there was no significant difference in the values of the IOP for the right eye between the GJ and GA ( $P = 0.195$ ); neither for the left eye, between the same groups ( $P = 0.307$ ).

#### *Conjunctival cytology*

The samples for conjunctival cytology presented high cellularity, revealing the same cellular pattern between young and adult goats. A predominance of superficial epithelial cells was observed, and also, in decreasing order of predominance, the presence of intermediate epithelial, squamous, basal, and calciform cells (Figure 1). A variable quantity of lymphocytes and rare neutrophils were also found.

## **DISCUSSION**

Schirmer's tear test, tonometry, and cytology are elementary analyzes for the assessment of eye health, as well as for monitoring important ophthalmic conditions. This is the first study that characterizes and describes normal conjunctival cells and describes reference values for STT and IOP in young and adult Moxotó goats.

The average value of the STT obtained in the GA ( $11.65 \pm 3.16$  mm/min) was similar to that found in the Alpine ibex (*Capra ibex*,  $11.7 \pm 3.87$  mm/min) (KVAPIL *et al.*, 2018); close to the Arabian oryx (*Oryx leucoryx*,  $12.7 \pm 4.8$  mm/min) (OFRI *et al.*, 1999); within the range of normality found in Pygmy goats (*Capra hircus*, 10-30 mm/min) (BROADWATER *et al.*, 2007); and below the ones found in the Nubian ibex (*Capra ibex nubiana*,  $13.2 \pm 5.1$  mm/min) (OFRI *et al.*, 1999), Saanen goats (*Capra aegagrus hircus*,  $13.8 \pm 0.66$  mm/min) (RIBEIRO *et al.*, 2010), Alpine Chamois (*Rupicapra rupicapra*,  $14.5 \pm 3.0$  mm/min), and Mouflons (*Ovis orientalis musimon*,  $17.9 \pm 3.87$  mm/min) (KVAPIL *et al.*, 2018). Concerning the GJ, the average value obtained in the STT ( $9.9 \pm 2.97$  mm/min) was close to the one found in 45-day-old Saanen goats (*Capra aegagrus hircus*,  $10.38 \pm 0.23$  mm/min), and below the value identified in 180-day-old animals from this same species ( $14.83 \pm 0.33$  mm/min) (RIBEIRO *et al.*, 2010), and their age was equivalent to the animals of the GJ in this study.

The results of this research revealed that the average value of the STT was significantly higher in adult goats (over one year of age) when compared to the average obtained in young ones (4 months of age), corroborating the observations in horses (BROOKS *et al.*, 2000) and pigs (TRBOLOVA & SELK GHAFARI, 2011). The values of the STT differ significantly between this species and animals of the same family (OFRI *et al.*, 2002; ORIÁ *et al.*, 2014; KVAPIL *et al.*, 2018; BEZERRA *et al.*, 2019). This fact proposes that some conjectures, particularly the level of stress throughout the capture, environmental factors, anesthetic protocols, living conditions (in the wild or captivity), age, and time of the day could influence these values (ARNETT *et al.*, 1984; RIBEIRO *et al.*, 2010). Low values of tear production can be found after sedation and anesthesia (ARNETT *et al.*, 1984; SANCHEZ *et al.*, 2006). Even though the animals of this study were restrained and examined in their habitual environment; without sedation or anesthesia, with no demonstrations of excessive restriction during the study, with their familiarity with frequent handling; the influence of some level of stress must be considered, especially regarding young goats, that were still becoming used to this process. This could result in sympathetic stimulation, reducing the tear secretion (GIULIANO & MOORE, 2007). Likewise, in a study with deers (*Mazama gouazoubira*), low values in the STT were obtained even after manual restraint, without sedation or anesthesia (MARTINS *et al.*, 2007).

Furthermore, lower values of tear production have also been referenced in animals that live in arid regions (OFRI *et al.*, 1999; OFRI *et al.*, 2001; MARTINS *et al.*, 2007), a fact that could explain the relatively low values of STT obtained in this research, bearing in mind that the Moxotó breed is native of the Brazilian Northeast and has adaptive characteristics which enable their survival in semi-arid regions (OLIVEIRA, 2004).

The average value of the IOP for GA ( $11.18 \pm 2.54$  mmHg) was similar to that obtained in the Arabian oryx (*O. leucoryx*,  $11.76 \pm 3.43$  mmHg) (OFRI *et al.*, 1998); close to the value found in Pygmy goats (*C. hircus*,  $10.8 \pm 1.7$  mmHg) (BROADWATER *et al.* 2007) and Alpine chamois (*R. rupicapra*,  $10.2 \pm 2.5$  mmHg) (KVAPIL *et al.*, 2018); within the interval of normality of values obtained in humans (10 – 20 mmHg) (MURGATROYD & BEMBRIDGE, 2008); and above the value found in 549-day-old Saanen goats (*Capra aegagrus hircus*,  $9.79 \pm 0.27$  mmHg) (RIBEIRO *et al.*, 2010). Regarding the species discussed here, except for the Arabian oryx, all were manually restrained. Furthermore, the measurements of the IOP in the studied goats were made using the Tonopen Vet<sup>®</sup>, however, in the species referenced above, the measurements were made with the Tonopen XL<sup>®</sup>, developed for use in humans.

The variations in the values of the IOP between closely related species (same Family or Subfamily), as those aforementioned, have already been discussed in other studies (KVAPIL *et al.*, 2018; BEZERRA *et al.*, 2019). This fact can be explained by the disparities in the methodologies applied, such as the methods of capture and restraint (Klein *et al.* 2011), the use of drugs for sedation and/or anesthesia (OFRI *et al.*, 1998; GATSON *et al.*, 2015), and different models of tonometer (GORIG *et al.*, 2006).

The average value of the IOP obtained in the GJ ( $10.10 \pm 2.40$  mmHg) was equivalent to the one described in Alpine chamois (*R. rupicapra*,  $10,2 \pm 2,5$  mmHg) (KVAPIL *et al.*, 2018) and Pygmy goats (*C. hircus*,  $10,8 \pm 1,7$  mmHg) (BROADWATER *et al.*, 2007); and discreetly higher than the one found in 180-day-old Saanen goats (*Capra aegagrus hircus*  $9.15 \pm 0.19$ ) (RIBEIRO *et al.*, 2010).

The conjunctival cytology analysis revealed similar types of cells as those described in other species (ABELLA *et al.*, 2007; VENÂNCIO *et al.*, 2012). Concerning the frequency of the cell types, the technique demonstrated a predominance of superficial and intermediate epithelial cells, as found in deer (MARTINS *et al.*, 2007), bovines (GONÇALVES *et al.*, 2012), and felines (VENÂNCIO *et al.*, 2012). Furthermore, the visualization of a variable quantity of lymphocytes, already described in domestic ruminants (WEYRAUCH, 1983), can be considered normal, since no ocular alterations, consistent with inflammation and/or infection, have been detected in the animals of this study (LAVACH *et al.*, 1997).

## CONCLUSION

It is concluded that the average value of the STT in adult Moxotó goats, over one year of age, is significantly higher than the one of young four-month-old goats, a fact that must be taken into consideration when evaluating this parameter in the previous species. Besides, the characterization of the conjunctival cellularity and the determination of the reference values for the STT and IOP, here established, will be able to adequately direct the achievement of the diagnosis and treatment of eye diseases in Moxotó goats, also collaborating in the scientific context in comparative ophthalmology studies.

## ACKNOWLEDGEMENTS

We would like to thank the Coordenação de Aperfeiçoamento de Pessoal de Nível Superior (CAPES) and those responsible for the Setor de Caprinocultura do Núcleo de Pesquisa do

Semiárido (NUPEÁRIDO) from the Universidade Federal de Campina Grande, Campus de Patos, Paraíba.

#### **CONFLICT OF INTEREST STATEMENT**

The authors declare no competing interests.

#### **ETHICS AND BIOSAFETY COMMITTEE**

The study was approved by the Ethics Committee on Animal Use from the Federal University of Campina Grande (CEUA-UFCG) under the protocol n. 101/2018 and was conducted according to the humane principles established in the ARVO Statement for the Use of Animals in Ophthalmic and Vision Research.

#### **CONTRIBUTION OF THE AUTHORS**

All authors have contributed equally to the conception and writing of the manuscript and critically reviewed and approved the final version.

#### **REFERÊNCIAS**

ABELLA, N.B. et al. Comparison of cytologic and histologic evaluations of the conjunctiva in the normal equine eye. **Veterinary Ophthalmology**, v.10, n.1, p.12-18, 2007. Available from: <<https://doi.org/10.1111/j.1463-5224.2007.00484.x>> Accessed: Mar. 28, 2019. doi: 10.1111/j.1463-5224.2007.00484.x.

ARNETT, B.D. et al. Effect of atropine sulfate on tear production in the cat when used with ketamine hydrochloride and acetylpromazine maleate. **Journal of the American Veterinary Medical Association**, v.185, n.2, p.214-215, 1984. Available from: <PMid:6746393> Accessed: Jun. 18, 2019.

BEZERRA, K.P.G. et al. Determination of baseline values for routine ophthalmic tests in bearded capuchin (*Sapajus libidinosus*). **Journal of Medical Primatology**, v.48, n.1, p.3-9,



2019. Available from: <<https://doi.org/10.1111/jmp.12378>>. Accessed: Mar. 08, 202. Doi: 10.1111/jmp.12378.

BROADWATER, J.J. et al. Ophthalmic examination findings in adult pygmy goats (*Capra hircus*). **Veterinary Ophthalmology**, v.10, n.5, p.269-273, 2007. Available from: <<https://doi.org/110.1111/j.1463-5224.2007.00548.x>> <PMid:17760703>. Accessed: Mar. 05, 2021. Doi: 10.1111/j.1463-5224.2007.00548.x.

BROOKS, D.E. et al. Cochet-Bonnet aesthesiometer-determined corneal sensitivity in neonatal foals and adult horses. **Veterinary Ophthalmology**, v. 3, n.2-3, p.133-137, 2000. Available from: <<https://doi.org/10.1046/j.1463-5224.2000.00125.x>> <PMid:11397295>. Accessed: Jul. 12, 202. doi: 10.1046/j.1463-5224.2000.00125.x.

GATSON, B.J. et al. Effects of premedication with sustained-release buprenorphine hydrochloride and anesthetic induction with ketamine hydrochloride or propofol in combination with diazepam on intraocular pressure in healthy sheep. **American Journal of Veterinary Research**, v.76, n.9, p.771-779, 2015. Available from: <<https://doi.org/10.2460/ajvr.76.9.771>> <PMid:26309105>. Accessed: Set. 22, 2020. doi: 10.2460/ajvr.76.9.771.

GIULIANO, E.A.; MOORE, C.P. Diseases and surgery of the lacrimal secretory system. In: GELATT, K.N. **Veterinary ophthalmology**. Florida: Black Well, 2007. Cap. 2. p.633-661 Accessed: Out. 03, 2020. 4.ed.

GONÇALVES, R.C. et al. Contagem de células conjuntivais por citologia de impressão em bovinos e equinos. **Revista Lusófona de Ciência e Medicina Veterinária**, v.5, p.56-63, 2012. Accessed: Apr. 21, 2018.

GORIG, C. et al. 2006. Comparison of the use of new handheld tonometers and established applanation tonometers in dogs. **American Journal of Veterinary Research**, v.67, n.1, p.134-144. Available from: <<https://doi.org/10.2460/ajvr.67.1.134>> <PMid:16426223 >. Accessed: Jun. 10, 2020. doi: 10.2460/ajvr.67.1.134

IBGE. INSTITUTO BRASILEIRO DE GEOGRAFIA E ESTATÍSTICA. Pesquisa Pecuária Municipal. 2018. Tabela 3939: efetivo dos rebanhos, por tipo de rebanho, 2018. [Rio de Janeiro, 2018]. Disponível em: <<https://sidra.ibge.gov.br/tabela/3939#resultado>>. Accessed: Jul. 30, 2021

KLEIN, H.E. et al. 2011. Effect of eyelid manipulation and manual jugular compression on intraocular pressure measurement in dogs. **Journal of the American Veterinary Medical Association**, v.238, n.10, p.1292-1295, 2011. Available from: <<https://doi.org/10.2460/javma.238.10.1292>> <PMid:21568774>. Accessed: Ago. 03, 2021. doi: 10.2460/javma.238.10.1292.

KVAPIL, P. et al. Tear production, intraocular pressure and conjunctival bacterial flora in selected captive wild ruminants. **Veterinary Ophthalmology**, v.21, n.1, p.52-57, 2018. Available from: <<https://doi.org/10.1111/vop.12478>>. Accessed: Fev. 17, 2020. doi: 10.1111/vop.12478.

LAVACH, J.D., et al. Cytology of normal and inflamed conjunctivas in dogs and cats. **Journal of the American Veterinary Medical Association**, v.170, n.7, p.722-727, 1997. Available from: <PMid:858688>. Accessed: Jul. 02, 2020.

LIMA, L. et al. The chinchila eye: morphologic observations, echobiometric findings and reference values for selected ophthalmic diagnostic tests. **Veterinary Ophthalmology**, 13(1):14-25, 2010. Available from: <<https://doi.org/10.1111/j.1463-5224.2010.00785.x>> <PMid:20840086>. Accessed: Jul. 30, 2021. doi: 10.1111/j.1463-5224.2010.00785.x.

MARTINS, M.S. et al. Ophthalmic patterns of captive brown brocket deer (*Mazama gouazoubira*). *Journal of Zoo and Wildlife Medicine*, v.38, n.4, p.526-532, 2007. Available from: <<https://doi.org/10.1638/MS05-084.1>> <PMid:18229857>. Accessed: Set. 30, 202. doi: 10.1638/MS05-084.1.

MCLELLAN, G.J.; MILLER, P.E. Feline glaucoma – A comprehensive review. **Veterinary Ophthalmology**, v.14, n.1, p.15-29, 2011. Available from: <<https://doi.org/10.1111/j.1463-5224.2011.00912.x>> <PMid:21923820>. Accessed: Out. 13, 2020. doi: 10.1111/j.1463-5224.2011.00912.x.

MONTIANI-FERREIRA, F. et al. Reference values for selected ophthalmic diagnostic tests of the capuchin monkey (*Cebus apella*). **Veterinary Ophthalmology**, v.11, n.3, p.197-201, 2008. Available from: <<https://doi.org/10.1111/j.1463-5224.2008.00620.x>> <PMid:18435663>. Accessed: Dez. 16, 2020. doi: 10.1111/j.1463-5224.2008.00620.x.

MURGATROYD, H.; BEMBRIDGE, J. Intraocular pressure. **Continuing Education in Anaesthesia, Critical Care & Pain**, v.8, n.3, p.100-103, 2008. Available from: <<https://doi.org/10.1093/bjaceaccp/mkn015>> Accessed: Dez. 18, 2020. doi: 10.1093/bjaceaccp/mkn015.

OFRI, R., et al. Intraocular pressure and tear production in captive eland and fallow deer. **Journal of Wildlife Diseases**, v.37, n.2, p.387-390, 2001. Available from: <<https://doi.org/10.7589/0090-3558-37.2.387>>. Accessed: Jan. 25, 2019. doi: 10.7589/0090-3558-37.2.387.

OFRI, R. et al. Tear production in three captive wild herbivores in Israel. **Journal of Wildlife Diseases**, v..35, n.1, p.134-136, 1999. Available from: <<https://doi.org/10.7589/0090-3558-35.1.134>> <PMid: PMID:10073364>. Accessed: Jan. 14, 2020. Doi: 10.7589/0090-3558-35.1.134.

OFRI, R. et al. Tonometry in three herbivorous wildlife species. **Veterinary Ophthalmology**, v.1, n.1, 21-24, 1998. Available from: <<https://doi.org/10.1046/j.1463-5224.1998.00004.x>>. Accessed: Mar. 25, 2019. doi: 10.1046/j.1463-5224.1998.00004.x.

OFRI R., et al. Intraocular pressure and tear production in five herbivorous wildlife species. **Veterinary Record**, v.151, n.9, p.265-268, 2002. Available from: <<https://doi.org/10.1136/vr.151.9.265>> <PMid:12233828>. Accessed: Out. 25, 2019. doi: 10.1136/vr.151.9.265.

OLIVEIRA, J.C.V. **Caracterização e perfil etnológico de rebanhos caprinos nos Municípios de Ibimirim e Serra Talhada, Estado de Pernambuco**. 2004. 60f. Dissertação (Mestrado em zootecnia), Pós-graduação em Zootecnia, Universidade Federal Rural de Pernambuco.

ORÍÁ, A.P. et al. Selected ophthalmic diagnostic tests, bony orbit anatomy, and ocular histology in sambar deer (*Rusa unicolor*). **Veterinary Ophthalmology**, v.18, n.1, p.1-7, 2014. Available from: <<https://doi.org/10.1111/vop.12221>> <PMid:25273613> Accessed: Jun. 10, 2019. doi: 0.1111/vop.12221.

PIGATTO, J.A.P. Intraocular pressure measurement in sheep using an applanation tonometer. **Revista Ceres**, v.58, n.6, p.685-689, 2011. Available from: <<https://doi.org/10.1590/S0034-737X2011000600002>>. Accessed: Jan. 25, 2021. doi: 10.1590/S0034-737X2011000600002.

RIBEIRO, A.P. et al. Intraocular pressure and tear secretion in Saanen goats with different ages. **Pesquisa Veterinária Brasileira**, v.30, n.9, p.798-802, 2010. Available from: <<https://doi.org/10.1590/S0100-736X2010000900015>>. Accessed: Jan. 14, 2021. doi: 10.1590/S0100-736X2010000900015.

SANCHEZ, R.F. et al. Effects of medetomidine and medetomidine-butorphanol combination on Schirmer tear test I readings in dogs. **Veterinary Ophthalmology**, v.9, n.1, p.33-37, 2006. Available from: <<https://doi.org/10.1111/j.1463-5224.2005.00432.x>> <PMid:16409243>. Accessed: Apr. 25, 2021. doi: 10.1111/j.1463-5224.2005.00432.x.

SANTOS, R.P. et al. Identification of naturalized goat breeds under conservation from Northeastern Brazil using chromosomal markers. **Genetics and Molecular Research**, v.12, n.3, p.3193-3200, 2013. Available from: <<https://doi.org/10.4238/2013>>. Accessed: Oct. 25, 2019. doi:10.4238/2013.

SOUZA, B.B., et al. Caprinos e ovinos adaptados aos trópicos. **Journal of Animal Behaviour and Biometeorology**, v.3, n.2, p.42-50, 2015. Available from: <<http://dx.doi.org/10.14269/2318-1265/jabb.v3n2p42-50>>. Accessed: Oct. 26, 2019. doi: 10.14269/2318-1265/jabb.v3n2p42-50

TRBOLOVA, A.; SELK, GHAFARI, M. Reference values for Schirmer tear tests I and II in clinically normal pigs. **Veterinary Ophthalmology**, v.15, n.3, p.180-182, 2012. Available from: <<https://doi.org/10.1111/j.1463-5224.2011.00960.x>> <PMid:22050769>. Accessed: Ago. 02, 2021. doi: 0.1111/j.1463-5224.2011.00960.x.

VENÂNCIO, S.A.S. et al. Avaliação da técnica de esfoliação com escova citológica para coleta de células conjuntivais em gatos saudáveis: comparação entre a face palpebral da membrana nictitante e a conjuntiva palpebral. **Pesquisa Veterinária Brasileira**, v.32, n.11, p.1199-1204, 2012. Available from: <<https://doi.org/10.1590/S0100-736X2012001100022>> Accessed: Jul. 02, 2021. doi: 10.1590/S0100-736X2012001100022.

WEYRAUCH, K.D. The conjunctival epithelium in the domestic ruminants. I. Lightmicroscopic investigations. **Zeitschrift fur mikroskopisch-anatomische Forschung**, v.97, n.4, p.565-572, 1983. Accessed: Dez. 18, 2020.

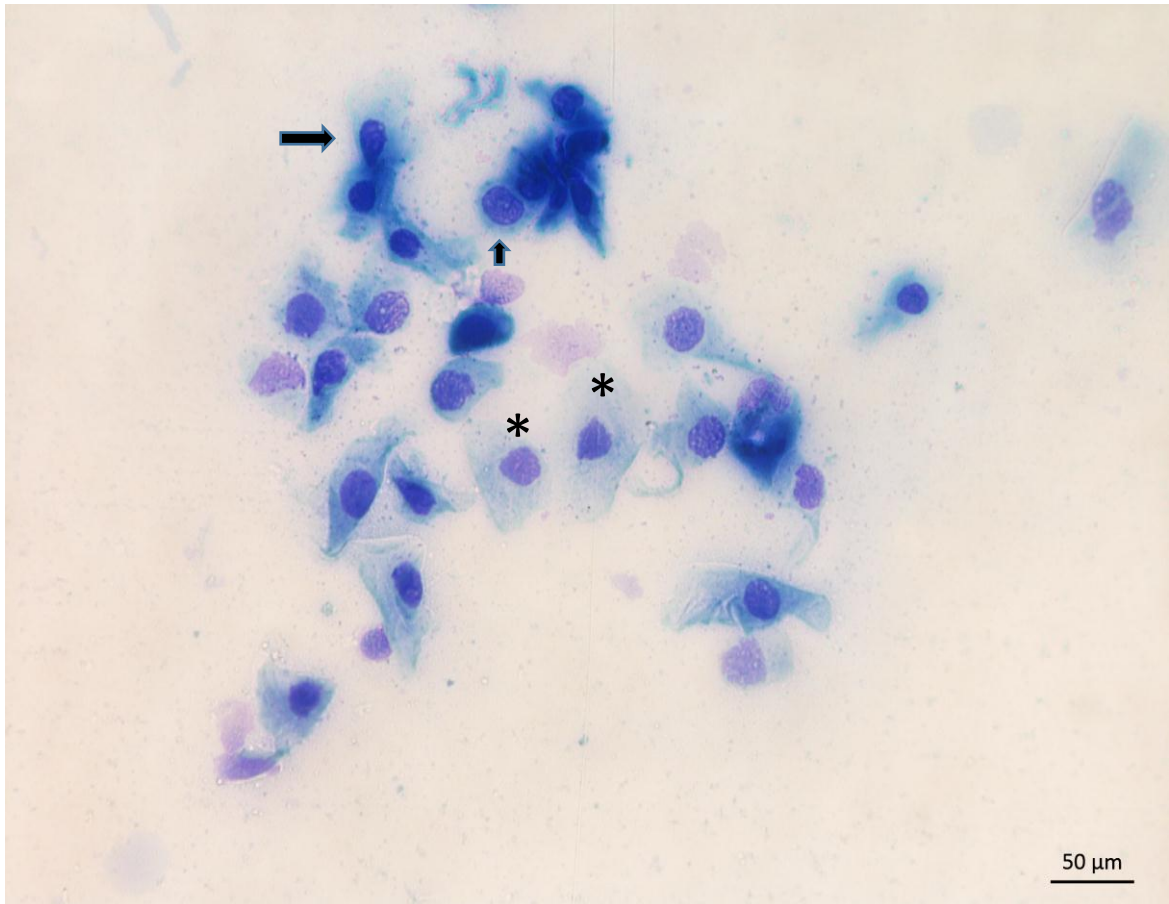
WILLIS, M. et al. 1997. Conjunctival brush cytology: evaluation of a new cytological collection technique in dogs and cats with a comparison to conjunctival scraping. **Veterinary & comparative ophthalmology**, v.7, n.2, p.74-81, 1997. Accessed: Dez. 18, 2020.

Table 1. Mean and standard deviation for tear production, obtained by Schirmer's tear test, and intraocular pressure in young and adult Moxotó goats.

	Ophthalmic tests	
	Schirmer's tear test (mm/min)	Intraocular pressure (mmHg)
Adult goats (GA)	11.65 ± 3.16*	11.18 ± 2.54
Young goats (GJ)	9.90 ± 2.97*	10.10 ± 2.40

\*significant difference between mean values (P=0.033).

**Figure 1.** Conjunctival cytology of a healthy Moxotó goat (*Capra aegagrus hircus*). Detail of the predominance of superficial epithelial cells (asterisk); in a smaller number, the squamous epithelial cells (big arrow) and basal cell (small arrow) are observed. Diff Quick-3 Panoptic.Obj.40x), [Bar = 50µm].



### **CAPÍTULO III:**

**Reference values for ophthalmic diagnostic tests and conjunctival cell characterization of black-chested buzzard-eagles (*Geranaetus melanoleucus*) and white-tailed hawks (*Geranaetus albicaudatus*)**

Artigo submetido à revista *Pesquisa Veterinária Brasileira* - Qualis A4



**Reference values for ophthalmic diagnostic tests and conjunctival cell characterization of black-chested buzzard-eagles (*Geranaetus melanoleucus*) and white-tailed hawks (*Geranaetus albicaudatus*)<sup>1</sup>**

Karla P.G. Bezerra<sup>2\*</sup>, Magda Fernandes<sup>3</sup>, Glenison F. Dias<sup>4</sup>, Nailson A.N. Júnior<sup>5</sup>, Ricardo B. Lucena<sup>6</sup>, Danila B. Campos<sup>6</sup>, Almir P. Souza<sup>2</sup>, Ivica C. Talieri<sup>6</sup>

**ABSTRACT.-** Bezerra K.P.G., Fernandes M., Dias G.F., Neri Júnior N.A., Lucena R.B., Campos D.B., Souza A.P. & Talieri I.C. **Reference values for ophthalmic diagnostic tests and conjunctival cell characterization of black-chested buzzard-eagles (*Geranaetus melanoleucus*) and white-tailed hawks (*Geranaetus albicaudatus*).** *Pesquisa Veterinária Brasileira*. 00(0):00-00. Postgraduate Program in Science and Animal Health, Federal University of Campina Grande, Center for Rural Health and Technology, Avenida Universitária, s/n - Santa Cecília, Patos, PB, 58708-110, Brazil. \*Corresponding author: [priscilagarridomv@gmail.com](mailto:priscilagarridomv@gmail.com)

The eye is the most important sensory organ for some birds, especially for birds of prey; however, basic studies on ocular physiology related to some bird species are still scarce. The lack of basic reference data for routine ophthalmic tests makes the diagnosis and adequate treatment of eye disorders difficult, and it is known that the physiological baseline values of ophthalmic tests established for some species should not be extrapolated, even among closely related ones. Thus, the objective was to determine reference values for the Schirmer -1 tear test (STT-1) and intraocular pressure (IOP) and to characterize the conjunctival cells black-chested buzzard-eagles (*Geranaetus melanoleucus*) and white-tailed hawks (*Geranaetus albicaudatus*). For that, three birds from each species were used. The mean value obtained in the STT was  $18.33 \pm 5.46$  mm/min for the black-chested buzzard-

---

<sup>1</sup> Received on

Accepted for publication on

<sup>2</sup> Programa de Pós-Graduação em Ciência e Saúde Animal, Universidade Federal de Campina Grande, Centro do Saúde e Tecnologia Rural, Avenida Universitária, s/n - Santa Cecília, Patos, PB, 58708-110, Brasil.

\*Corresponding author: [priscilagarridomv@gmail.com](mailto:priscilagarridomv@gmail.com)

<sup>3</sup> Programa de Pós-Graduação em Medicina Veterinária, Universidade Federal Rural de Pernambuco, Rua Dom Manoel de Medeiros, s/n – Dois Irmãos, 52.171.900, Recife, Pernambuco, Brasil.

<sup>4</sup> Médico Veterinário, Ecohawks Serviços Ambientais, João Pessoa, Paraíba, Brasil.

<sup>5</sup> Residência Multiprofissional de Clínica Médica e Cirúrgica de Animais Silvestres, Programa Multiprofissional da Universidade Federal do Pará, Campus Castanhal, Av. dos Universitários, s/n - Jaderlândia, Castanhal, Pará, 68746-630, Brasil.

<sup>6</sup> Departamento de Medicina Veterinária, Universidade Federal da Paraíba, Campus II, 12 Rodovia, PB-079, 58397 Areia, Paraíba, Brasil.

eagles and  $11 \pm 3.46$  mm/min for white-tailed hawks. The mean IOP values were  $23.67 \pm 3.2$  mmHg for the first, and  $23.5 \pm 2.59$  mmHg for the latter. The conjunctival cytological analysis revealed numerous cellularity and demonstrated that the conjunctival cells of the studied species have the same morphological characteristics, with a predominance of intermediate and superficial squamous cells. Varying degrees of cytoplasmic granulation of melanocytes were observed in samples from the left eye of subjects from both species. Some erythrocytes and bacterial aggregates were also visualized. Furthermore, a variable amount of heterophils was found. The reference values of the ophthalmic tests obtained in this study, as well as the characterization of conjunctival cells, will be useful to fill the gaps in ophthalmic knowledge concerning these species.

INDEXING TERMS: ophthalmology, Schirmer's tear test, intraocular pressure, conjunctival cytology, birds of prey.

**RESUMO.- [Valores de referência para testes de diagnóstico oftálmico e caracterização celular conjuntival de águias-chilenas (*Geranaetus melanoleucus*) e de gaviões-de-rabo-branco (*Geranaetus albicaudatus*)].** O olho é o órgão sensorial mais importante para algumas aves, principalmente no que se refere às rapinantes; porém, estudos básicos sobre a fisiologia ocular voltados a algumas espécies de aves ainda são escassos. A carência de dados básicos referenciais para os testes oftálmicos de rotina dificulta o diagnóstico e o tratamento adequado das afecções oculares e é sabido que os valores basais fisiológicos de testes oftálmicos estabelecidos para algumas espécies não devem ser extrapolados, mesmo entre as intimamente relacionadas. Assim, objetivou-se determinar valores referenciais para o teste lacrimal de Schirmer -1 (TLS-1) e pressão intraocular (PIO), e caracterizar as células conjuntivais de águias-chilenas (*Geranaetus melanoleucus*) e de gaviões-do-rabo-branco (*Geranaetus albicaudatus*). Para tanto, utilizou-se três aves de cada espécie. O valor médio obtido no TLS foi de  $18,33 \pm 5,46$  mm/min para as águias-chilenas e  $11 \pm 3,46$  mm/min para os gaviões-de-rabo-branco. Os valores médios da PIO foram:  $23,67 \pm 3,2$  mmHg para as águias-chilenas e  $23,5 \pm 2,59$  mmHg para os gaviões-de-rabo-branco. As análises citológicas conjuntivais revelaram numerosa celularidade e demonstraram que as células da conjuntiva das espécies estudadas possuem as mesmas características morfológicas, com predominância de células superficiais escamosas e intermediárias. Observou-se graus variados de granulação

melanocítica citoplasmática em amostras do olho esquerdo de uma águia-chilena e de um gavião-de-rabo-branco. Alguns eritrócitos e agregados bacterianos foram visualizados. Ademais, uma quantidade variável de heterófilos foi constatada. Os valores de referência dos testes oftálmicos obtidos nesse estudo, bem como a caracterização de células conjuntivais serão úteis frente às lacunas do conhecimento oftálmico para as espécies *Geranaetus melanoleucus* e *Geranaetus albicaudatus*.

TERMOS DE INDEXAÇÃO: oftalmologia, teste lacrimal de Schirmer, pressão intraocular, citologia conjuntival, aves de rapina.

## INTRODUCTION

There has been an increase in the number of wild and exotic birds in rehabilitation centers, either by voluntary delivery or seizure through the competent organs (Environmental Police, Brazilian Institute for the Environment and Renewable Natural Resources - IBAMA). These species; kept in zoos, rehabilitation centers, and educational institutions; provide the opportunity to conduct studies to obtain descriptive data, and provide information on the physiology of various systems, which would contribute to the conservation of wild fauna.

As a result of the urbanization process, the presence of birds in the urban environments has become more frequent, a fact that directly contributes to the increase in trauma, due to collisions with various obstacles, as cars, electric poles, glass windows, and buildings (Carvalho & Marini 2007, Labelle et al. 2012, Kuhn et al. 2013). As a result, these animals are sent to rehabilitation centers presenting several affections, among them, the ocular ones. However, their ophthalmic structure has peculiarities and variations (Murphy & Murphy 1997, Labelle et al. 2012), making the diagnosis of ophthalmic diseases a challenge. Birds of prey have very large eyeballs in relation to the body, and they are protruding from the skull, characteristics that make them more susceptible to trauma (Harris et al. 2008, Labelle et al. 2012, Seruca et al. 2012).

Considering that the eye is the most important sensory organ for some birds, especially birds of prey (Korbel 2016) - as they need good visual acuity for hunting and other survival conditions - veterinarians in rehabilitation centers, zoos and other institutions must have access to consolidated basic referential data of ophthalmic tests, to avoid obtaining erroneous diagnoses and empirically performing treatments.

Birds of prey comprise four distinct orders: Cathartiformes (old world vultures and condors), Strigiformes (owls and little owls), Falconiformes (hawks and crested caracaras), and Accipitriformes (hawks, eagles, and buzzards). The black-chested buzzard-eagle (*Geranoaetus melanoleucus*) is a neotropical species of the *Accipitridae* family. Its distribution area involves the Andes Mountains, Venezuela, Brazil, and Chile; the white-tailed hawk (*Geranoaetus albicaudatus*) is a species of bird of prey of the *Accipitridae* family, found in the southern United States to Central America, northern Argentina, Colombia, Venezuela, Peru, Paraguay and Brazil (Sick 1997).

Ophthalmology has become an essential specialty with regard to maintaining the health of the eyes of wild animals and exotic species. Even so, basic studies on ocular physiology focused on some bird species, especially national ones, are still scarce. The lack of basic reference data for routine ophthalmic tests makes the diagnosis and adequate treatment of eye disorders difficult, despite the contributions obtained for some species of birds of prey (Harris et al., 2008; Labelle et al. 2012, Kuhn et al., 2013, Beckwith-Cohen et al. 2015), even with a low number of subjects from some genera (Stiles et al. 1994, Reuter et al. 2011, Smith et al. 2015, Beckwith-Cohen et al. 2015). It is attested that basal physiological values of ophthalmic tests applicable to these species should not be extrapolated, even among closely correlated ones, considering that the basal values of Schirmer's tear test and intraocular pressure vary considerably between species, as well and between individuals of the same family (Ofri et al. 2002, Komnenou et al. 2013).

Given this gap, the objective was to determine reference values for the Schirmer's tear test and the intraocular pressure, as well as to characterize the conjunctival cells of black-chested buzzard-eagles (*Geranaetus melanoleucus*) and white-tailed hawks (*Geranaetus albicaudatus*).

## MATERIAL AND METHODS

**Ethics statement.** The study was authorized by the Biodiversity Authorization and Information System of the Ministry of the Environment of Brazil, under license No. 55724-1. In addition, it was conducted following the guidelines from the National Council for the Control of Animal Experimentation (CONCEA) and the human principles set out in the

ARVO Declaration (*Statement for the Use of Animals in Ophthalmic and Vision Research*) on the Use of Animals in Ophthalmologic Research.

**Animals.** Three black-chested buzzard-eagles (*Geranaetus melanoleucus*) and three white-tailed hawks (*Geranaetus albicaudatus*), one male and two females from both species, residents at the Parque Zoobotânico Arruda Câmara, in João Pessoa, Paraíba, Brazil, were used. All birds were captured with the help of a bird net and leather gloves, and then underwent a general clinical routine and ophthalmic examination, to exclude from the study the ones with clinical signs of systemic and/or ocular disease.

**Eye exam.** Both eyes and periocular regions were inspected under normal light and with a magnifying glass to detect macroscopic changes. Neuro-ophthalmic examinations (menace reflex test, pupillary light reflex, eyelid, and corneal reflex) were performed to attest to ocular integrity. From this, healthy birds were selected and submitted to the following order of data and sample collection: i) evaluation of tear production by Schirmer's tear test 1 (STT-1); ii) measurement of intraocular pressure (IOP); iii) conjunctival cytology. To avoid discrepancies, the ophthalmic tests were performed by the same evaluator throughout the collection.

**Schirmer 1 tear test (STT-1).** Schirmer's tear test preceded the other analyzes so that tear production was not influenced by eye drops or clinical procedures. Standardized millimeter strips of STT absorbent papers (Schirmer® Tear Test, Ophthalmos Formulas, São Paulo, SP, Brazil) were inserted in the inferior conjunctival fornix of both eyes from each bird, where they remained for one minute. Immediately after this interval, the moistened portion was measured (mm/min) (Fig.1).

**Intraocular pressure (IOP).** The IOP of both eyes was measured with the aid of a portable applanation tonometer (Tono-Pen AVIA®, Reichert Technologies, Buffalo, USA) after instillation of anesthetic eye drops based on 0.5% proxymetacaine hydrochloride (Anestalcon®, Alcon Laboratories of Brazil, São Paulo, Brazil). The final result (mean obtained by the device) of the first successful reading of the tonometer was recorded, with a maximum standard deviation of 5% for each eye (Fig.1).

**Conjunctival cytology.** Conjunctival samples were collected with the aid of a sterile cytological brush (Kolplast®, São Paulo, Brazil) by carefully exfoliating the inferior conjunctival fornix of both eyes from each animal (Fig.1). The samples were distributed on a microscope slide using the rolling method, dried at room temperature, stained by the rapid Panoptic method, and evaluated by direct microscopy, with 40X and 100X magnification. Macroscopically, no lesions were observed in the conjunctiva after collection.

## RESULTS

### Schirmer's tear test 1 (STT-1)

The mean value obtained in the STT was  $18.33 \pm 5.46$  mm/min for the black-chested buzzard-eagles (*G. melanoleucus*) and  $11 \pm 3.46$  mm/min for white-tailed hawks (*G. albicaudatus*) (Table 1).

### Intraocular pressure (IOP)

The mean IOP values were  $23.67 \pm 3.2$  mmHg for black-chested buzzard-eagles (*G. melanoleucus*) and  $23.5 \pm 2.59$  mmHg for white-tailed hawks (*G. albicaudatus*) (Table 1).

### Conjunctival cytology

The conjunctival cytological analyzes revealed numerous cellularity and demonstrated that the conjunctival cells of the studied species have the same morphological characteristics, with a predominance of intermediate and superficial squamous cells. Varying degrees of cytoplasmic granulation of melanocytes were observed in samples from the left eye of a black-chested buzzard-eagle (*G. melanoleucus*) and a white-tailed hawk (*G. albicaudatus*). Some erythrocytes and bacterial aggregates were visualized. Furthermore, a variable amount of heterophils was found.

## DISCUSSION

The good functioning of the visual system is essential for birds, especially concerning free-living species of birds of prey. With the fragmentation of their natural habitat and illegal trafficking, the arrival of these animals in rehabilitation centers, preservation areas, and/or zoos, carrying several diseases; including ocular ones, which are not diagnosed and treated efficiently due to the lack of basic referential data about ophthalmic diagnostic tests; has been more frequent.

The specimens studied here have tolerated the performance of STT-1 well, without sedation, and allowed the tape to remain in the conjunctival fornix for the time required to assess tear production. The STT is a valuable part of the ophthalmic examination and is essential for evaluating the function of the tear glands as it allows measuring the production of the aqueous component through the tear film (Montiani-Ferreira et al. 2008).

In the present study, the mean value of STT-1 obtained in black-chested buzzard-eagles (*G. melanoleucus* -  $18.33 \pm 5.46$  mm/min) was higher than that obtained in other species of birds of prey evaluated by the same test – common kestrel (*Falco tinnunculu* -  $6.20 \pm 3.67$  mm/min), short-toed snake eagle (*Circaetus gallicus* -  $7.5 \pm 3.5$  mm/min) (Beckwith-

Cohen et al. 2015), common buzzard (*Buteo buteo* -  $12.47 \pm 2.66$  mm/min) (Barsotti et al. 2013), western marsh harrier (*Circus aeruginosus* -  $12 \pm 5.6$  mm/min) (Beckwith-Cohen et al. 2015), bald eagle (*Haliaeetus leucocephalus* -  $14 \pm 2$  mm/min) (Kuhn et al. 2013) and pharaoh eagle-owl (*Bubo ascalaphus* -  $15 \pm 0$  min/min) (Beckwith-Cohen et al. 2015) – and close to that obtained in larger birds, as the common ostriches (*Struthio camelus* -  $16.3 \pm 2.5$  mm/min) (Ghaffarii et al. 2012).

In the study with bald eagles (*H. leucocephalus*) (Kuhn et al. 2013), the largest bird of prey from the ones discussed here, the authors reported that the mean value for STT was higher than that found for most bird species in other researches; however, in black-chested buzzard-eagles (*G. melanoleucus*), the second-largest, the value obtained exceeded that reported in birds of the aforementioned species. This could be explained by the fact that they were transported for approximately one hour to the study site and certainly some degree of stress must be considered, possibly resulting in a sympathetic stimulus, reducing tear secretion (Giuliano & Moore, 2007).

The mean value found for STT-1 ( $11 \pm 3.46$  mm/min) in the white-tailed hawks (*G. albicaudatus*) studied was close to that obtained in the common buzzard (*B. buteo* -  $12.47 \pm 2.66$  mm/min) (Barsotti et al. 2013) and western marsh harrier (*C. aeruginosus* -  $12 \pm 5.6$  mm/min) (Beckwith-Cohen et al. 2015); above that found in the black kite (*M. migrans* -  $7.4 \pm 5.7$  mm/min), short-toed snake eagle (*Circaetus gallicus* -  $7.5 \pm 3.5$  mm/min) and Montagu's harrier (*Circus pygargus* -  $8 \pm 2.8$  mm/min) (Beckwith-Cohen et al. 2015); and below that reported in the bald eagle (*H. leucocephalus* -  $14 \pm 2$  mm/min) (Kuhn et al. 2013) and in the pharaoh eagle-owl (*B. ascalaphus* -  $15 \pm 0$  min/min) (Beckwith-Cohen et al. 2015).

These disparities in STT values can be explained by differences in size between species, as well as variations in orbit size, and in the size and function of the lacrimal gland (Williams 1994). Furthermore, some environmental factors, age and time of day, as well as the level of stress during capture, can influence them (Arnett et al. 1984, Ribeiro et al. 2010). As described in some studies, STT values vary widely between species, even closely correlated, and between individuals of the same family (Ofri et al. 2002, Oriá et al. 2014, Kvapil et al. 2018, Bezerra et al. 2019).

The mean values of IOP, obtained by applanation tonometry, in black-chested buzzard-eagles (*G. melanoleucus* -  $23.67 \pm 3.2$  mmHg) and white-tailed hawks (*G. albicaudatus* -  $23.5 \pm 2, 59$  mmHg), in this research, were similar and close to those reported, by the same technique, in other birds of prey, as bald eagles (*H. leucocephalus* -  $21.5 \pm 1.7$  mmHg) (Kuhn et al. 2013), golden eagles (*Aquila chrysaetos* -  $21.5 \pm 3.0$  mmHg) (Stiles et al.

1994), red-tailed hawks (*Buteo jamaicensis* -  $20.3 \pm 2.8$  mmHg) (Labelle et al. 2012), steppe buzzard (*Buteo buteo vulpinus* -  $25.0 \pm 1.6$  mmHg); and above those obtained in common kestrels (*F. tinnunculus* -  $8.53 \pm 1.59$  mmHg) (Barsotti et al. 2013), cooper's hawks (*Accipiter cooperii* -  $16.0 \pm 1.8$  mmHg) (Labelle et al. al. 2012), black kites (*M. migrans* -  $17.1 \pm 7.2$  mmHg) (Beckwith-Cohen et al. 2015), common buzzards (*B. buteo* -  $17.2 \pm 3.53$  mmHg) (Barsotti et al. al. 2013) and in short-toed snake eagles (*C. gallicus* -  $18.6 \pm 2.2$  mmHg) (Beckwith-Cohen et al. 2015). The variations found in the IOP values among these species are possibly due to differences in the methodologies used, such as capture and containment methods (Klein et al. 2011), different models of tonometer (Gorig et al. 2006, 2006). Pereira et al 2011), differences in the shapes and sizes of eye bulbs, the thickness and curvature of the cornea, and the influence of the circadian cycle on the regulation and formation of aqueous humor (Stiles et al. 1994; Pereira et al. 2011; Labelle et al. 2012).

The variability in STT and IOP values reinforces the precision of establishing reference values for each species, even among those closely related (Ofri et al. 2002), and warns of the risk of extrapolating them from one species to another. Therefore, even if the number of birds studied here is low, given the limited availability of black-chested buzzard-eagles (*G. melanoleucus*) and white-tailed hawks (*G. albicaudatus*) in captivity, it is believed that the values obtained may be applicable as normality parameters for STT and IOP in these species.

The conjunctival cytological analysis of the studied birds showed cellularity similar to descriptions in healthy animals of other species, including horses, monkeys, and cats (Abella et al. 2007, Venâncio et al. 2012, Oriá et al. 2013, Bezerra et al. 2019). The visualization of heterophils and bacteria can be considered normal as there were no ocular clinical signs consistent with inflammation and/or infection (Lavach et al. 1997).

## CONCLUSION

The reference values of the ophthalmic tests obtained in this study, as well as the characterization of conjunctival cells, will be useful, considering the gaps in ophthalmic knowledge for the species *Geranaetus melanoleucus* and *Geranaetus albicaudatus*.

**Acknowledgments.** - We would like to thank the Coordenação de Aperfeiçoamento de Pessoal de Nível Superior (CAPES) and Roberto Citelli de Farias, a Veterinarian, experienced



in the Wild and Exotic Animal Practice, for handling the birds during collections at the Parque Zoobotânico Arruda Câmara.

**Conflict of interest.** - The authors declare no conflict of interest.

## REFERÊNCIAS

- Abella N.B., Letron I.R., Diquelou A., Guillot E., Regnier A. & Trumel C. 2007. Comparison of cytologic and histologic evaluations of the conjunctiva in the normal equine eye. *Vet. Ophthalmol.* 10(1):12-18. <<https://doi.org/10.1111/j.1463-5224.2007.00484.x>><PMid: 17204123>
- Arnett B.D., Brightman A.H. & Musselman E.E. 1984. Effect of atropine sulfate on tear production in the cat when used with ketamine hydrochloride and acetylpromazine maleate. *J. Am. Vet. Med. Assoc.* 185(2):214-215. <PMid:6746393>
- Barsotti G.; Briganti A.; Spratte J. R.; Ceccherelli R. & Breggi G. 2013. Schirmer tear test type I readings and intraocular pressure values assessed by applanation tonometry (Tonopen® XL) in normal eyes of four European species of birds of prey. *Vet. Ophthalmol.* 16(5):365-36. < <https://doi.org/10.1111/vop.12008>>
- Beckwith-Cohen B., Horowitz I., Bdolah-Abram T., Lublin A. & Ofri R. 2015. Differences in ocular parameters between diurnal and nocturnal raptors. *Vet Ophthalmol.* 18(1):98-105. <<https://doi.org/10.1111/vop.12126>>
- Bezerra K.P.G., Lucena R.B.L., Stipp D.T., Costa F.S., Reis V.V., Borges P.F., Bopp S., Campos D.B. & Talieri I.C. 2019. Determination of baseline values for routine ophthalmic tests in bearded capuchin (*Sapajus libidinosus*). *J. Med. Primatol.* 48(1):3-9. <<https://doi.org/10.1111/jmp.12378>> <PMid: 30230553>
- Carvalho C.E.A. & Marini M.A. 2007. Distribution patterns of diurnal raptors in open and forested habitats in south-eastern Brazil and the effects of urbanization. *Bird Conserv. Inter.* 17(04):367-380. <<https://doi.org/10.1017/S0959270907000822>>

- Ghaffari M.S., Sabzevari A., Vahedi H. & Golezardy K. 2012. Determination of reference values for intraocular pressure and schirmer tear test in clinically normal ostriches (*struthio camelus*). J. Zoo Wildl. Med. 43(2):229-232. <<https://doi.org/10.2307/41681823>><PMid:22779224>
- Giuliano E.A. 2013. p. 912-937. Diseases and surgery of the canine lacrimal secretory system. In: Gelatt K.N., Gilger B.C. & Kern T.J. (Eds). Veterinary Ophthalmology. 5<sup>a</sup> ed. Ames: Wiley-Blackwell.
- Gorig C., Coenen R.T., Stades F.C., Djajadiningrat-Laanen S.C. & Boevé M.H. 2006. Comparison of the use of new handheld tonometers and established applanation tonometers in dogs. Am. J. Vet. Res. 67(1):134-144. <<https://doi.org/10.2460/ajvr.67.1.134>> <PMid:16426223>
- Harris M. C.; Schorling J.J., Herring I.P., Elvinger F., Bright P.R. & Pickett J.P. 2008. Ophthalmic examination findings in a colony of Screech owls (*Megascops asio*). Vet. Ophthalmol. 11(3):186-192. <<https://doi.org/10.1111/j.1463-5224.2008.00618.x>><PMid:18435661>
- Jiménez J.E. & Jaksic F.M. 1990. Historia natural del águila *Geranoaetus melanoleucus*: una revisión. Hornero. 13(2):97-110.
- Kommenou A.T., Thomas A.L.N., Danika S.E., Skartsi T., Vasilakis D.P., Cárcamo B. & Ofri R. 2013. Estimation of normal tear production in free-living Eurasian black vultures (*Aegypius monachus*) and Griffon vultures (*Gyps fulvus*) in Dadia National Park, Greece. J Zoo Wildl Med. 44(2):315-322. <<https://doi.org/10.1638/2012-0144R1.1>>
- Korbel R. 2016. Avian ophthalmology - principles and application. Proc Annu Conf Europ Assoc Avian Vet. 275-282.
- Kuhn S.E.; Jones M.P., Hendrix D.V H., Ward D.A. & Baine K.H. 2013. Normal Ocular Parameters and Characterization of Ophthalmic Lesions in a Group of Captive Bald Eagles. J. Avian Med. Surg. 27(2):90-98. <<https://doi.org/10.1647/2012-032>><PMid:23971217>

- Kvapil P., Pirs T., Slavec B., Lustrik R., Zemljic T., Bártoová E., Stranjac B. & Kastelic M. 2018. Tear production, intraocular pressure and conjunctival bacterial flora in selected captive wild ruminants. *Vet. Ophthalmol.* 21(1):52-57. <<https://doi.org/10.1111/vop.12478>><PMid: 28493440>
- Labelle A.L., Whittington J.K., Breaux C.B., Labelle P., Mitchell M.A., Zarfoss M.K., Schmidt S.A. & Hamor R.E. 2012. Clinical utility of a complete diagnostic protocol for the ocular evaluation of free-living raptors. *Vet Ophthalmol.* 15(1):5-17. <<https://doi.org/10.1111/j.1463-5224.2011.00899.x>>
- Lavach J.D., Thrall M.A., Benjamin M.M. & Severin G.A. 1997. Cytology of normal and inflamed conjunctivas in dogs and cats. *J. Am. Vet. Med. Assoc.* 170(7):722-727. <PMid:858688>
- Montiani-Ferreira. F., Truppel J., Tramontin M.H., Vilani R.G.D. & Lange R.R. 2008. The capybara eye: clinical tests, anatomic and biometric features. *Vet. Ophthalmol.* 11(6):386-394. <<https://doi.org/10.1111/j.1463-5224.2008.00663.x>>
- Murphy, P. J; Murphy, C, J. 1997. It's the Same, Only Different. *Semin Avian Exot Pet Med.* 6(3):107.
- Ofri R., Horowitz I.H., Raz D., Shvartsman E. & Kass P.H. 2002. Intraocular pressure and tear production in five herbivorous wildlife species. *Vet. Rec.* 151(9):265-268. <<https://doi.org/10.1136/vr.151.9.265>> <PMid:12233828>
- Oriá A.P., Junior D.C.G., Oliveira A.V.D., Curvelo V.P., Estrela-Lima A., Pinna M.H., Meneses Í.D.S., Filho E.F.M. & Ofri R. 2014. Selected ophthalmic diagnostic tests, bony orbit anatomy, and ocular histology in sambar deer (*Rusa unicolor*). *Vet. Ophthalmol.* 18(1):1-7. <<https://doi.org/10.1111/vop.12221>><PMid:25273613>
- Oriá A.P., Pinna M.H., Almeida D.S., Silva R.M.M., Pinheiro [A.C.O.](#), Santana [F.O.](#), Costa [T.R.](#), [Meneses](#) Í.D.R., [Martins Filho](#) E.F., [Oliveira](#) A.V.D. 2013. Conjunctival flora, Schirmer's tear test, intraocular pressure, and conjunctival cytology in neotropical primates from Salvador, Brazil. *J. Medic. Primatol.* 42(6):287-292. <<https://doi.org/10.1111/jmp.12059>><PMID: 23879249>

- Pereira F.Q., Bercht B.S., Soares M.G., Mota M.G. & Pigatto J.A. 2011. Comparison of a rebound and an applanation tonometer for measuring intraocular pressure in normal rabbits. *Vet. Ophthalmol.* 14(5):321-326. <<https://doi.org/10.1111/j.1463-5224.2011.00879.x>><PMid: 21929609>
- Ribeiro A.P., Piso D.Y.T., Padua I.R.M., Silva M.L. & Laus J.L. 2010. Intraocular pressure and tear secretion in Saanen goats with different ages. *Pesq. Vet. Bras.* 30(9):798-802. <<https://doi.org/10.1590/S0100-736X2010000900015>>
- Seruca C., Molina-Lopez R., Pena T. & Leiva M. 2012. Ocular consequences of blunt trauma in two species of nocturnal raptors (*Athene noctua* and *Otus scops*). *Vet Ophthalmol.* 15(4):236-244. <<https://doi.org/10.1111/j.1463-5224.2011.00976.x>>
- Sick H. 1997. *Ornitologia Brasileira*. 2ªed. Nova Fronteira, Rio de Janeiro, p.143-519.
- Smith S.P., Barbon A.R. & Forbes N.A. 2015. Evaluation of the phenol red thread test in falconiformes. *J Avian Med Surg.* 29(1):25–29. <<https://doi.org/10.1647/2008-050>>
- Stiles J., Buyukmihci N.C. & Farver T.B. 1994. Tonometry of normal eyes in raptors. *Am J Vet Res.* 55(4):477-479.
- Venâncio S.A.S., Vieira A.B., Alencar N.X. & Soares A.M.B. 2012. Avaliação da técnica de esfoliação com escova citológica para coleta de células conjuntivais em gatos saudáveis: comparação entre a face palpebral da membrana nictitante e a conjuntiva palpebral. *Pesq. Vet. Bras.* 32 (11):1199-1204. <<https://doi.org/10.1590/S0100-736X2012001100022>>
- Williams D. 1994. Ophthalmology, p.682-686. In: Ritchie B.W., Harrison G.J. & Harrison L.R. (Eds), *Avian Medicine: Principles and application*. Winger's Publishing Inc., Lake Worth, FL.

### Legend for the Figure

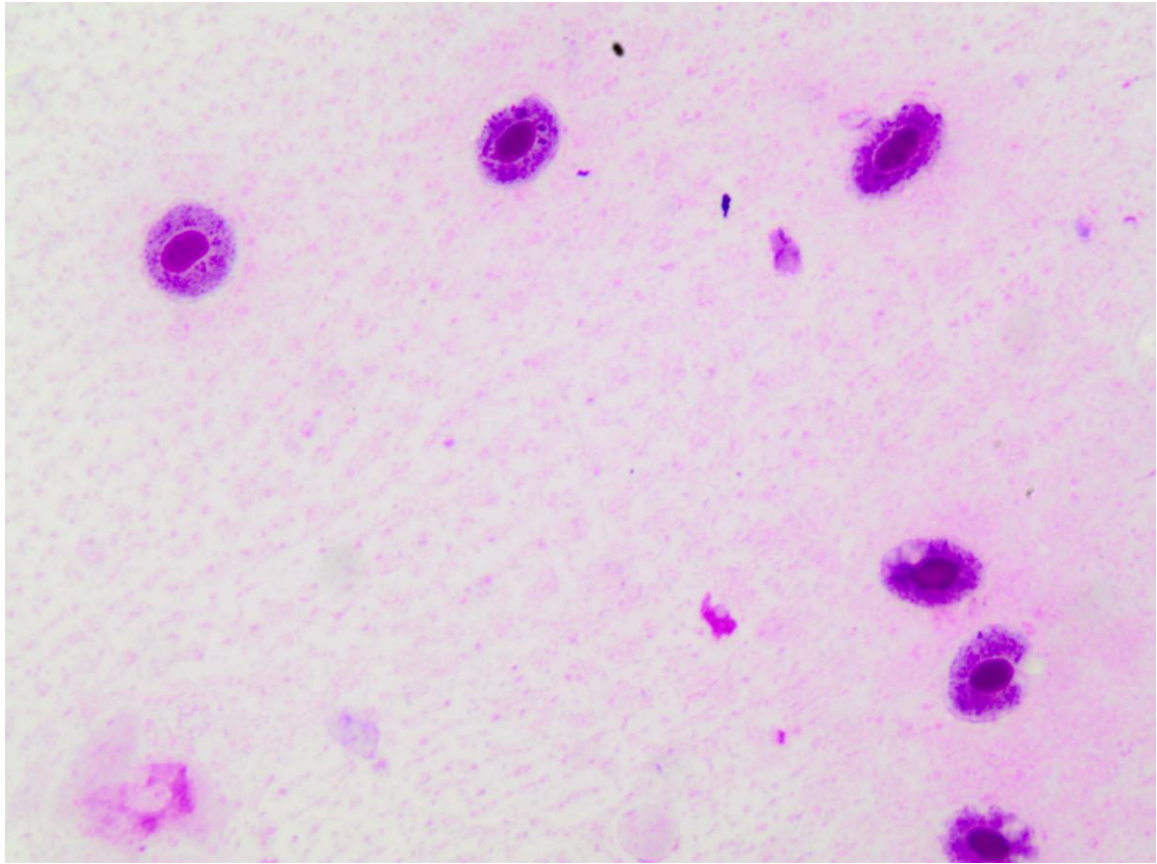
Fig.1. (A-C) Ophthalmic tests on white-tailed hawk (*Geranaetus albicaudatus*), healthy, resident at the Parque Zoobotânico Arruda Câmara, João Pessoa, Paraíba, Brazil. (A) Schirmer's tear test (B) exfoliative conjunctival cytology (C) applanation tonometry.

Fig.2. Conjunctival cytology of a healthy white-tailed hawk (*Geranaetus albicaudatus*). A variable amount of heterophils is observed. Diff Quick-Panoptic.Obj.100x.

Fig.1

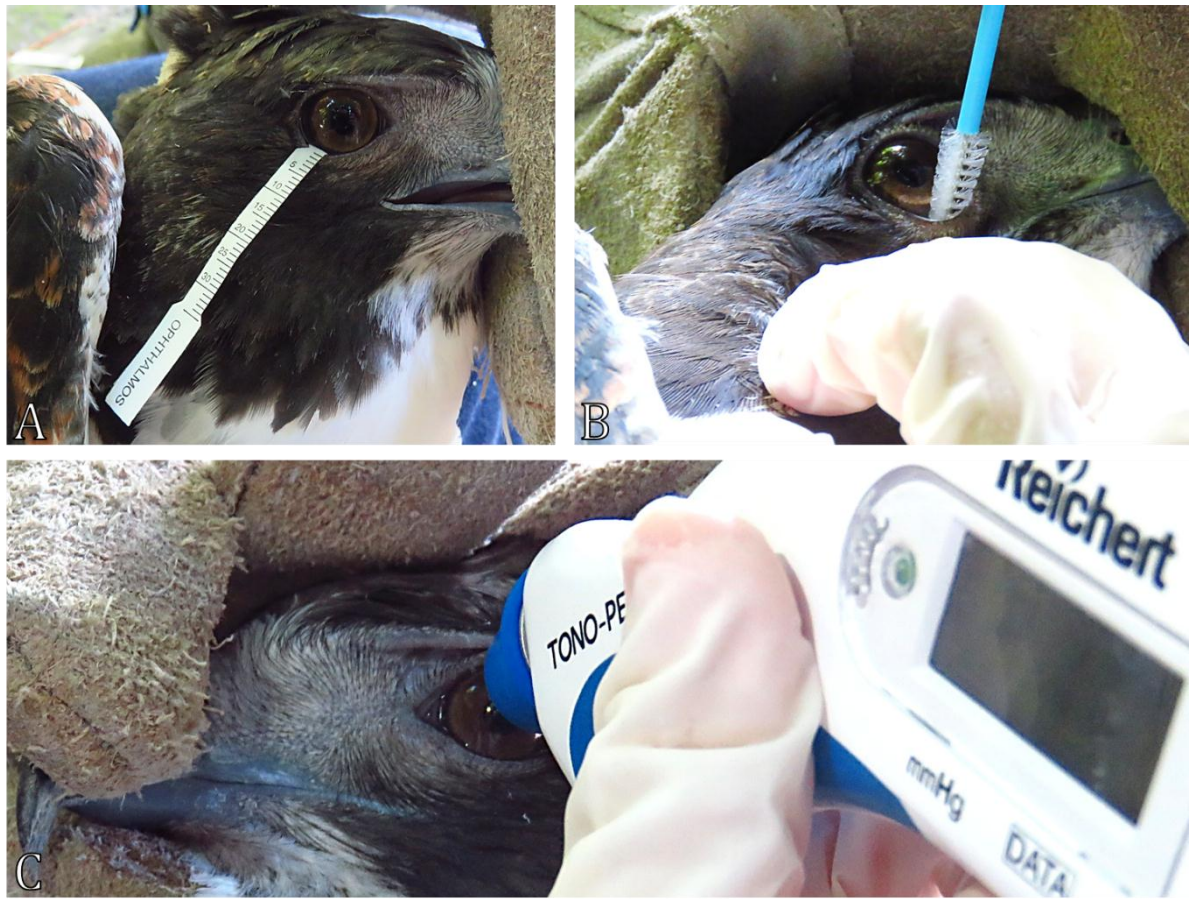

Fig.2



**Table 1. Mean and standard deviation for Schirmer's tear test and intraocular pressure in black-chested buzzard-eagles (*Geranaeus melanoleucus*) and white-tailed hawks (*Geranaetus albicaudatus*)**

Species	Ophthalmic tests	
	Schirmer's tear test	intraocular pressure
	(mm/min)	(mmHg)
	Mean ± Standard Deviation	Mean ± Standard Deviation
<i>Geranaeus melanoleucus</i>	18,33 ± 5,46	23,67 ± 3,2
<i>Geranaetus albicaudatus</i>	11 ± 3,46	23,5 ± 2,59



## CONSIDERAÇÕES GERAIS

Diante dos resultados obtidos nos três artigos que integram esta tese, pôde-se chegar às seguintes conclusões:

- As amostras das conjuntivas oculares são valiosas para obtenção do diagnóstico de leishmaniose em gatos e poderá subsidiar outras investigações acerca da doença;
- A aplicabilidade de diferentes técnicas de diagnóstico a variadas amostras biológicas é importante a fim de se evitar a subestimação de casos dessa zoonose;
- Os valores de referência dos testes oftálmicos estabelecidos neste estudo, bem como a caracterização das células conjuntivais irão subsidiar o diagnóstico e o tratamento adequado diante de afecções oculares na espécie caprina nativa (Moxotó), em águias-chilenas (*Geranaeus melanoleucus*) e em gaviões-de-rabo-branco (*Geranaetus albicaudatus*).