



UNIVERSIDADE FEDERAL DE CAMPINA GRANDE
CENTRO DE SAÚDE E TECNOLOGIA RURAL
UNIDADE ACADÊMICA DE MEDICINA VETERINÁRIA
PROGRAMA DE PÓS-GRADUAÇÃO EM CIÊNCIA E SAÚDE ANIMAL

Francisco Alipio de Sousa Segundo

Desenvolvimento e aplicação de implante a base da associação de wollastonita, β -TCP e PEGDMA para tratamento de defeito segmentar ósseo em coelhos

Patos/PB
2022

Francisco Alipio de Sousa Segundo

Desenvolvimento e aplicação de implante a base da associação de wollastonita, β -TCP e PEGDMA para tratamento de defeito segmentar ósseo em coelhos

Dissertação submetida ao Programa de Pós-graduação em Ciência e Saúde Animal da Universidade Federal de Campina Grande, como requisito parcial para obtenção do grau de Mestre em Ciência e Saúde Animal.

Orientador: Prof. Dr. Marcelo Jorge Cavalcanti de Sá

Patos/PB
2022

S725d

Sousa Segundo, Francisco Alipio de.

Desenvolvimento e aplicação de implante a base da associação de wollastonita, β -TCP e PEGDMA para tratamento de defeito segmentar ósseo em coelhos / Francisco Alipio de Sousa Segundo. – Patos, 2022.

48 f. : il. color.

Dissertação (Mestrado em Ciência e Saúde Animal) – Universidade Federal de Campina Grande, Centro de Saúde e Tecnologia Rural, 2022.

"Orientação: Prof. Dr. Marcelo Jorge Cavalcanti de Sá".

Referências.

1. Biomateriais. 2. Cerâmicas. 3. *In vivo*. 4. Cirurgia Experimental. 5. Polímero. 6. Regeneração. I. Sá, Marcelo Jorge Cavalcanti de. II. Título.

CDU 61:62(043)



MINISTÉRIO DA EDUCAÇÃO
UNIVERSIDADE FEDERAL DE CAMPINA GRANDE
POS-GRADUACAO EM CIENCIA E SAUDE ANIMAL
Rua Aprigio Veloso, 882, - Bairro Universitario, Campina Grande/PB, CEP 58429-900

FOLHA DE ASSINATURA PARA TESES E DISSERTAÇÕES

FRANCISCO ALÍPIO DE SOUSA SEGUNDO

DESENVOLVIMENTO E APLICAÇÃO DE IMPLANTE A BASE DA ASSOCIAÇÃO DE WOLLASTONITA, β -TCP E PEGDMA PARA TRATAMENTO DE DEFEITO SEGMENTAR ÓSSEO EM COELHOS

Dissertação apresentada ao Programa de Pós-Graduação em Ciência e Saúde Animal como pré-requisito para obtenção do título de Mestre em Ciência e Saúde Animal.

Aprovada em: 29/08/2022

BANCA EXAMINADORA:

Prof. Dr. Marcelo Jorge Cavalcanti de Sá (Orientador - PPGCSA/UFCG)

Prof. Dr. João Moreira da Costa Neto (Examinador Externo - UFBA)

Prof. Dr. Gabriel Goetten de Lima (Examinador Externo - UFPR)



Documento assinado eletronicamente por **Gabriel Goetten de Lima, Usuário Externo**, em 29/08/2022, às 12:03, conforme horário oficial de Brasília, com fundamento no art. 8º, caput, da [Portaria SEI nº 002, de 25 de outubro de 2018](#).



Documento assinado eletronicamente por **MARCELO JORGE CAVALCANTI DE SA, PROFESSOR(A) DO MAGISTERIO SUPERIOR**, em 30/08/2022, às 09:39, conforme horário oficial de Brasília, com fundamento no art. 8º, caput, da [Portaria SEI nº 002, de 25 de outubro de 2018](#).



Documento assinado eletronicamente por **João Moreira da Costa Neto, Usuário Externo**, em 30/08/2022, às 09:40, conforme horário oficial de Brasília, com fundamento no art. 8º, caput, da [Portaria SEI nº 002, de 25 de outubro de 2018](#).



A autenticidade deste documento pode ser conferida no site <https://sei.ufcg.edu.br/autenticidade>, informando o código verificador **2627353** e o código CRC **9C8BFDA1**.

AGRADECIMENTOS

Agradeço primeiramente à força celestial por todas as oportunidades apresentadas e por me permitir aproveitá-las.

A minha família, em especial à Taynara e a Guilherme, os quais me ensinam diariamente a me tornar uma pessoa melhor.

Ao professor Marcelo Sá, meu orientador, por toda paciência e por acreditar em meu potencial.

Agradeço a todos que realmente contribuíram de forma positiva com o trabalho, jamais serão esquecidos por mim e possuem minha gratidão onde estiverem.

“Se eu vi mais longe, foi porque estava sobre os ombros de gigantes”.
Sir Isaac Newton – 1675.

RESUMO

As tentativas de reparar grandes lesões ósseas são desafiadoras, para facilitar esse processo é possível utilizar biomateriais que estimulem a regeneração deste tecido, para isto é possível utilizar materiais isolados ou associados. O presente trabalho se propõe a realizar um apanhado do que se vem trabalhando atualmente com a aplicação do dimetacrilato de polietilenoglicol (PEGDMA) sobre o reparo do tecido ósseo, bem como apresentar um compósito desenvolvido com a associação do PEGDMA com as cerâmicas de beta trisfosfato de cálcio (β -TCP) e Wollastonita para regenerar defeitos segmentares ósseos em coelhos. Nesse processo levou-se em consideração principalmente ensaios *in vivo*. Diversas avaliações podem ser realizadas para acompanhar a interação dos compósitos no organismo, incluindo exames de imagem e histopatológicos. Os resultados positivos relatados com a utilização de compósitos a base de polímeros como o PEGDMA, também puderam ser observados no presente estudo, sendo uma excelente opção para associação, seja com medicações, cerâmicas ou outros polímeros.

Palavras-chave: Biomateriais; Cerâmicas; *In vivo*; Polímero; Regeneração;

ABSTRACT

Attempts to repair large bone lesions are challenging, to facilitate this process it is possible to use biomaterials that stimulate the regeneration of this tissue, for this it is possible to use isolated or associated materials. The present work proposes to carry out an overview of what is currently being worked on with the application of ethylene glycol dimethacrylate (PEGDMA) on the repair of bone tissue, as well as to present a composite developed with the association of PEGDMA with the beta trisphosphate ceramics of calcium (β -TCP) and Wollastonite to regenerate bone segmental defects in rabbits. In this process, mainly *in vivo* assays were taken into account. Several evaluations can be performed to monitor the interaction of composites in the body, including imaging and histopathological exams. The positive results reported with the use of composites based on polymers such as polyethylene glycol, could also be observed in the present study, being an excellent option for association, whether with medications, ceramics or other polymers.

Keywords: Biomaterials; Ceramics; *In vivo*; Polymer; Regeneration;

LISTA DE FIGURAS

	Página
Figure 1 – Flowchart of the records found, selected and included.....	18
Figure 2 – Lateral radiographic images of the middle third of the radius and ulna of rabbits in the implant (IG) and control (CG) groups at different times after the surgical procedure. Bone defect region (red arrow).....	34
Figura 3 – Figure 3 – Radio and ulna tomographic images of rabbits in the implant (IG) and control (CG) groups at different times after the surgical procedure.....	36
Figure 4 – Longitudinal histopathological section of the osteotomy site without implants at 60 days postoperatively. A defect (A) is observed between cortices (B), filled with little newly formed bone tissue (C). 40x magnification.....	40
Figure 5 – Longitudinal histopathological section of the bone/implant interface at 60 days postoperatively. A large amount of newly formed bone tissue (A) in the process of maturation is observed, with some blood vessels (arrows) connecting the cortices. 40x magnification.....	40
Figure 6 – Longitudinal histopathological section of the osteotomy site without implants at 120 days postoperatively. The presence of a defect (A) between cortices is observed, filled by moderate neoformed bone tissue (B). 40x magnification.....	41
Figure 7 – Longitudinal histopathological section of the bone/implant interface at 120 days postoperatively. The presence of a remnant of biomaterial is observed (A), surrounded by little connective tissue (B). Above the biomaterial, an osteotomy region in an advanced stage of healing is observed, with the formation of more compact bone (C) and several blood vessels (arrows). 40x magnification.....	41

LISTA DE TABELAS

	Página
Table 1 – Description of authors, study model, composite composition, main application of PEGDMA polymer, animal species studied, number of animals, whether there was a control group and study period.....	19
Table 2 – Description of authors, bone studied, defect size used, evaluations performed and summary of results.....	20
Table 3 – Mean values and standard deviation of radiographic evaluation scores of the implant groups (IG) and control group (CG) in relation to alignment, apparatus and biological activity at different times after the surgical procedure.....	35
Table 4 – Mean values and standard deviation of tomographic evaluation scores of the implant groups (IG) and control group (CG) in relation to tissue neoformation and neotissue mineralization at different times after the surgical procedure.....	37
Table 5 – Mean values and standard deviation in μm of the histomorphometric evaluation of the implant groups (IG) and control group (CG) in relation to tissue quantification at different times after the surgical procedure.....	39

LISTA DE SÍMBOLOS, SIGLAS E ABREVIATURAS

PEGDMA	Polietileno glicol dimetacrilato
SLC	Sistema de liberação controlada
Esp	Espécie
N	Amostra experimental
G	Grupos experimentais
GC	Grupo controle
Micro	Microscopia ótica de luz
MOD	Matriz óssea desmineralizada
HA	Hidroxiapatita
PC	Policaprolactona
PLLA	Poliácido láctico
siRNA	Pequenas moléculas de RNA
PCL	Policaprolactona
APG	Ácido poliglicólico
APL	Poliácido láctico
Q	Quitosana
AMD	Ácido metacrílico
FCP	Fator de crescimento plaquetário
B-TCP	Beta-trifosfatato de cálcio
TGI	Trato gastrointestinal
uTC	Micro Tomografia Computadorizada
F	Fluorescência
Radio	Radiografia
Histo	Histopatologia
Imuno	Imunohistoquímico
W	Wallostonita
UV	Ultravioleta
GI	Grupo implante
mg	Miligrama
kg	Kilograma
mm	Milímetro

SUMÁRIO

	Página
RESUMO.....	7
ABSTRACT.....	8
LISTA DE FIGURAS.....	9
LISTA DE TABELAS.....	10
LISTA DE ABREVIACÕES.....	11
INTRODUÇÃO GERAL.....	12
REFERÊNCIAS.....	13
CAPÍTULO I: Ethylene glycol dimethacrylate (PEGDMA) as a repairer of bone defects: Systematic review.....	14
ABSTRACT	15
INTRODUCTION.....	15
DATA SELECTION.....	16
RESULTS.....	17
DISCUSSION.....	21
CONCLUSIONS.....	22
REFERENCES.....	23
CAPÍTULO II: Development and application of an association of wollastonite, β-TCP and PEGDMA based implant for the treatment of segmental bone defect in rabbits.....	26
ABSTRACT.....	27
INTRODUCTION.....	28
MATERIALS AND METHODS.....	29
Obtaining biomaterials.....	29
<i>In vivo</i> study.....	29
Experimental groups.....	30
Pre-surgical preparation.....	30
Operative procedure.....	30
Clinical-orthopedic evaluation.....	31
Radiographic evaluation.....	31
Tomographic evaluation.....	31
Histopathological and morphometric evaluation.....	32
Statistical analysis.....	32
RESULTS AND DISCUSSION	32
Clinical-orthopedic evaluation.....	32
Radiographic evaluation.....	33
Tomographic evaluation.....	35
Histopathological and morphometric evaluation.....	38
CONCLUSIONS.....	42
REFERENCES.....	43
CONCLUSÕES.....	47

INTRODUÇÃO GERAL

As fraturas de ossos longos são os problemas mais comuns na rotina cirúrgica-ortopédica, podendo representar um sério problema para a saúde de pacientes acometidos, principalmente devido ao tempo de repouso forçado, incapacidade de exercer funções produtivas e em casos de complicações, a cicatrização do tecido ósseo pode ser um verdadeiro desafio para o cirurgião (BONAFEDE et al., 2013).

O tratamento comumente utilizado no reparo de fraturas é a estabilização com implantes, os quais proporcionam o compartilhamento e distribuição de forças aplicadas sobre o osso enquanto a atividade de células como osteoblastos é aumentada no foco da fratura proporcionando neoformação do tecido ósseo (EINHORN & GERSTENFELD, 2015).

Os diferentes implantes podem proporcionar diferentes estabilidades, as quais influenciam diretamente o tipo de cicatrização óssea, estabilidade rígida, com ausência de movimentação no foco da fratura, promove uma cicatrização óssea primária, estabilidades flexíveis, as quais promovem movimentação no foco da fratura, levam a formação de calo ósseo e cicatrização secundária (BOTTLANG et al., 2010)

Apesar da variedade de abordagens existentes para o tratamento de defeitos ósseos, a cicatrização desse tecido é limitada, fazendo com que alguns em alguns casos seja necessária a utilização de biomateriais para estimular a regeneração tecidual (CLAES et al., 2012).

Os biomateriais são produtos como polímeros e cerâmicas que possuem propriedades desejáveis para implantação no organismo como biocompatibilidade, nenhuma citotoxicidade e bioatividade (AZEVEDO et al., 2014).

Entre os biomateriais utilizados para reparo ósseo se destacam polímeros como o PEGDMA e as cerâmicas como o β -TCP e a Wollastonita, os quais possuem potencial como compósitos ou isolados, apresentando todas as propriedades desejáveis como biomateriais (TAVASSOLI et al., 2018).

Apesar dos relatos positivos com a aplicação desses materiais, ainda existe muitas melhorias possíveis tanto no desenvolvimento e fabricação dos compósitos como em sua própria aplicação (LIMA et al., 2019).

REFERÊNCIAS

AZEVEDO, A. S.; SÁ, M. J. C.; FOOK, M. V. L.; NETO, P. I. NÓBREGA; SOUSA, O. B.; AZEVEDO, S. S.; TEIXEIRA, M. W.; COSTA, F. S.; ARAÚJO, A. L. Use of chitosan and β -tricalcium phosphate, alone and in combination, for bone healing in rabbits. **Journal of Materials Science. Materials in Medicine (Dordrecht. Online)**, v. 25, p. 481-486, 2014.

BONAFEDE, M.; ESPINDLE, D.; BOWER, A.G. The direct and indirect costs of long bone fractures in a working age US population. **J. Med. Econ.** v. 16, n. 1, p. 169-178, 2013.

BOTTLANG, M.; LESSER, M.; KOERBER, J.; DOORNINK, J.; RECHENBERG, B.; AUGAT, P.; FITZPATRICK, D. C.; MADEY, S. M.; MARSH, J. L. Far cortical locking screws can improve healing of fractures stabilized with locking plates. **J. Bone Joint Surg. Am.** v. 92, n. 7, p. 1652-1660, 2010.

CLAES, L.; RECKNAGEL, S.; IGNATIUS, A. Fracture healing under healthy and inflammatory conditions. **Nat. Rev. Rheumatol.** v. 8, n. 3, p. 133-143, 2012.

EINHORN, T. A.; GERSTENFELD, L. C. Fracture healing: mechanisms and interventions. **Nat. Rev. Rheumatol.** v. 11, n. 1, p. 45-54, 2015.

LIMA, G. G.; ELTER, J. K.; CHEE, B. S.; MAGALHÃES, W. L. E.; DEVINE, D. M.; NUGENT, M. J. D.; SÁ, M. J. C. A tough and novel dual-response PAA/P(NiPAAM-co-PEGDMA) IPN hydrogels with ceramics by photopolymerization for consolidation of bone fragments following fracture. **Biomed. Mater.** v. 14. 2019.

TAVASSOLI H.; ALHOSSEINI, S. N.; TAY, A.; CHAN, P. P. Y.; WENG, O. S. K.; WARKIANI, M. E. Large-scale production of stem cells utilizing microcarriers: A biomaterials engineering perspective from academic research to commercialized products. **Biomaterials**, v. 181, p. 333-346. 2018.

CAPÍTULO I: Ethylene glycol dimethacrylate (PEGDMA) as a repairer of bone defects: Systematic review.

Trabalho a ser submetido à revista Acta Biomaterialia. ISSN: 1742-7061. Fator de Impacto: 8.9. Qualis A1.

Ethylene glycol dimethacrylate (PEGDMA) as a repairer of bone defects: Systematic review.

F. A. Sousa Segundo^a, M. J. C. Sá^b.

^aPrograma de Pós-Graduação em Ciência e Saúde Animal, Universidade Federal de Campina Grande (UFCG), Av. Universitária, s/n, Bairro Santa Cecília, Patos, PB, Brasil.

^bUnidade Acadêmica de Medicina Veterinária, UFCG, Av. Universitária, s/n, Bairro Santa Cecília, Patos, PB, Brasil.

ABSTRACT

The use of polymers such as PEGDMA in the health area has been highlighted due to its excellent biocompatibility properties and production versatility. The present review aims to gather studies on the use of polymers in their different applications. The survey of articles was carried out with the aid of electronic databases. Articles published between 2012-2022 in English and Portuguese were included. Results data from selected articles were collected, including authors, year of publication, materials used, experimental design, study duration, evaluations performed, and results. Although 100% of the articles included in this review reported positive results with the use of PEG-based composites, it is also reported that adjustments, better understanding and more evaluations are needed to complement the results presented.

KEYWORDS: Biomaterials; Drugs; Polymer; Tissue repair; Controlled release system;

1. Introduction

Bone segmental defects are defined as the loss of a significant fragment of bone, mainly affecting the long bones, this pathology can lead to a decrease in cortical and spongy bone stock and impairment of bone mechanical strength [1].

These defects represent a real challenge for the veterinary and human medical routine, this is mainly due to the limited ability of bone tissue to regenerate, making more invasive measures often necessary as treatment [2].

The multidisciplinary therapeutic approach makes it possible to expand the range of options in the treatment of defects that are so complex to treat, the association of areas such as materials engineering and medicine, allows the development of materials capable of stimulating the repair of various tissues or even serving as a mechanical framework for filling defects [3].

Biocompatibility, mechanical strength and bioactivity are desirable characteristics of materials used in tissue repair, polymers are materials that can present these characteristics, which facilitates their association with other materials and products with different purposes [4].

Several functions can be applied to polymers, the manufacture of composites that allow controlling the release of substances as well as improving the biocompatibility of other materials is an example of the most common use of polymers such as PEGDMA being a very versatile material [5].

PEGDMA has been extensively researched as a stimulant for bone tissue repair and positive results are reported, these results are associated with excellent biocompatibility and cellular stimulation caused by this polymer [6]. In addition, PEGDMA is quite versatile in its production, allowing several applications in the medical field [7].

In view of the above, the present review aims to gather studies and report the behavior of the use of polymers based mainly on PEGDMA.

2. Data selection

The survey of articles was carried out with the aid of electronic databases such as PubMed, BVS Salud and SCIELO, considering the period of publication between 2012-2022. Articles published in English and Portuguese were included, which evaluated the use of PEGDMA polymer applied in the repair of bone tissue and, finally, in vivo evaluations were performed. The index terms used in the search were: "PEGDMA", "dimethacrylate", "polyethylene", "glycol", "polymer", "material", "biopolymer", "biomaterial", "composite", "in vivo".

After the initial survey of articles, randomized clinical trials comparing treatment groups with the polymer versus control groups without materials were included. Literature reviews, meta-analyses and abstracts were discarded.

Results data from selected articles were collected, including authors, year of publication, materials used, experimental model, study duration, evaluations performed and results.

The qualitative results of the studies were compiled and presented in tables.

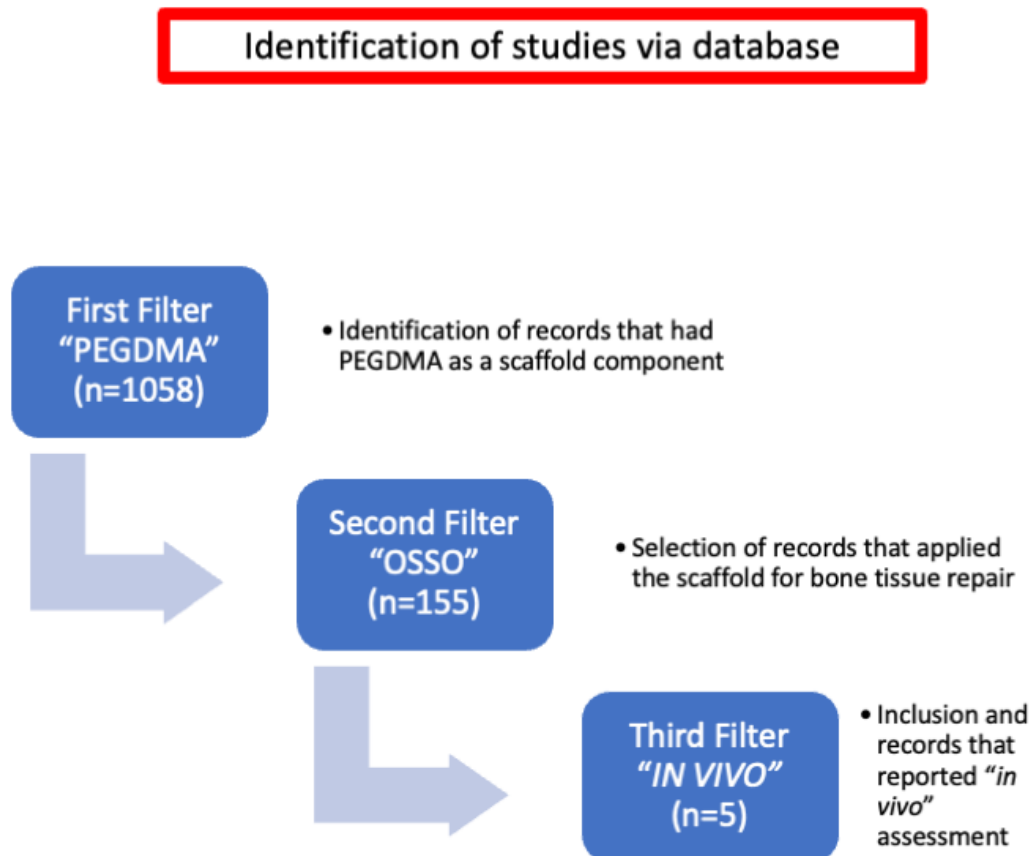
3. Results

A total of 1058 articles were found in the databases with the first keyword: PEGDMA, after the application of the second keyword: BONE, the number of articles was reduced to 155, finally, with the insertion of the third keyword: IN VIVO, a total of four articles were found, which were included in the present study (Fig. 1).

The use of the polymer as a controlled release system of substances represented 40% of the studies found, the other 60% represent an application as a porous structural support associated with other biomaterials such as biopolymers, ceramics and pluripotent cells (Table 1).

Several bones served as models of experimental fractures of different sizes, ranging from 0.5 to 5 mm. The evaluations most used in the follow-up of bone repair were histopathology and microtomography, participating in 100 and 80%, respectively (Table 2).

Figure 1 – Flowchart of the records found, selected and included.



Author	Study desing	Scaffold composition	Application	Species studied	N	Control Group	Trial period
ASENSIO et al., (2022)	Bone defect repair	PEGDMA + PLGA + β -TCP + Hialuronic acid + Strontium folate	Structural porous support	Rabbits	16	Yes	90 days
RIVERA et al., (2021)	Bone defect repair	PEGDMA + β -NGF	Controlled release system	Rats	n/i	Yes	21 days
GHIMIRE et al., (2019)	Bone infection treatment	PEGDMA + Vancomycin	Controlled release system	Rats	6	Yes	21 days
MA et al., (2017)	Bone defect repair	PEGDMA + Methacrylate gel + Pluripotent cells	Structural porous support	Rats	33	Yes	45 days
MARTIN-DEL-CAMPO et al., (2016)	Bone defect repair	PEGDMA + Chitosan + β -TCP + Pluripotent cells + Strontium folate	Structural porous support	Rats	18	Yes	150 days

Table 1 – Description of authors, study model, composite composition, main application of PEGDMA polymer, animal species studied, number of animals, whether there was a control group and study period.

Author	Bone studied	Defect size	Evaluations	Results
ASENSIO et al., (2022)	Femoral trochlea	4 mm	Histopathology	Evident neoformation of cartilage-like tissue
RIVERA et al., (2021)	Tibia	1 mm	Microtomography + Histopathology + Histomorphometry	Improving in bone fracture repair
GHIMIRE et al., (2019)	Femoral trochlea	0,5 mm	Microtomography + Bioluminescence + Culture + Histopathology	+ Effective prophylactic treatment against bone infection caused by <i>Staphylococcus aureus</i> .
MA et al., (2017)	Jaw	3 mm	Microtomography + Histopathology	Bone neoformation in greater quantity and more robust tissue
MARTIN-DEL-CAMPO et al., (2016)	Skull	5 mm	Microtomography + Histopathology	Stimulation of bone neoformation

Table 2 – Description of authors, bone studied, defect size used, evaluations performed and summary of results.

4. Discussion

A significant amount of work with PEGDMA was found in the evaluated period, showing a great interest in the subject, which is explained by the versatility of application, excellent characteristics presented for use in engineering and medicine, and the apparent ability to control the release of substances and /or compounds [8], despite this, few studies with in vivo evaluations in bone tissue were found.

The ease of associating PEGDMA with other products demonstrates the excellent biocompatibility with the organism, little or no cytotoxicity, ability to control the rate of degradation of polymers and excellent interaction between polymers and other products such as drugs, ceramics or other polymers [9].

With this biocompatibility, there is a decrease in the stimulus of foreign body in the body, decreasing the formation of fibrous tissue around the composites and causing a decrease in osmotic pressure and consequent decrease in water loss, which causes the release of some substances take longer [10].

In addition, the low cytotoxicity allows the adhesion and maintenance of undifferentiated cells and blood vessels at the implanted site, when implanted in bone tissue, this causes the association with ceramics to allow greater activity of cells such as osteoblasts and chondrocytes, thus accelerating the repair of this tissue [11].

Among the materials associated with PEGDMA we observed ceramics such as β -TCP, polymers such as Chitosan and Methacrylate, substances such as hyaluronic acid, strontium folate, vancomycin and β -NGF, in addition we also observed the association with pluripotent cells. The repair of bone tissue represented the objective of 80% of the works, evidencing the difficulty and importance of accelerating its regeneration [12], while the remaining 20% aimed at treating bone infection, which may be directly related to bone tissue repair. to repair this tissue.

Rats were the most used animals in in vivo evaluations, followed by rabbits, mainly due to the ease of handling, being the most used in several studies in the most varied areas of biology [13].

The experimental period ranged from 21 to 150 days in the different applications, all this variation shows a versatility in the degradation of the polymer that can be controlled in its production in addition to other aspects, according to some authors [14] a composite produced with a high particle ratio form, such as microrods, allows for a porous surface that enhances cell adhesion and the organism's interaction with the products or cells in the composite.

The relationship between degradation and release of substances by the composite and the possibility of controlling this makes it possible to maintain a constant serum concentration of the product in the tissue, as is also shown by [14], when they compared the release of Intravenous β -NGF or through microrods based on PEGDMA and β -NGF applied by injection in fractures produced in rat tibias.

The same constancy is observed with other products such as antibiotics, according to [15], a composite based on PEGDMA with vancomycin implanted in the femur of rats with osteomyelitis, were able to fully control bacterial proliferation and eliminate the infection, maintaining a constant local level of the antibiotic.

Different bone application sites were used in the studies, including skull, mandible, femur and tibia, with defect sizes ranging from 0.5 to 5 mm. This size variation shows the benefit of being able to produce a composite that can completely fill the defect, which is often limited in situations of autologous grafts that are the most routinely used [16].

Although 100% of the articles included in this review reported positive results with the use of PEGDMA-based composites, it is also reported that adjustments, better understanding and more evaluations are needed to complement the results presented, this is mainly due to the variation in the rate of polymer degradation, which can be manipulated according to the way the composite is produced [17].

A better understanding of the relationship between manufacturing and the interaction between the composite itself and the environment where it will be deployed is fundamental to guide the production process and in vivo application of the composite [18].

5. Conclusions

In view of what was found in the various articles presented in this review, the potential of polymers such as PEG in the formation of composites for tissue regeneration or controlled release of substances is evident.

The continuous development of studies is fundamental for the feasibility and approximation of the experimental to the practical routine.

References

- [1] M.M. Monção, R.C. Dourado, L.Q. Vasconceos, I.C. Barreto, R.P.C. Araújo, Analysis of the behavior of a biomaterial based on wollastonite/TCP in the implant process of an experimental model of critical bone defects, *Research, Society and Development*, 10, 7, (2021).
- [2] W.T. Barbosa, K.V. Almeida, G.G. Lima, M.A. Rodriguez, M.V.L. Fook, R. García-Carrodegas, V.A. Silva Junior, F.A. Sousa Segundo, M.J.C. Sá, Synthesis and in vivo evaluation of a scaffold containing wollastonite/ β -TCP for bone repair in a rabbit tibial defect, *Model. J. Biomed. Mater. Res.*, 108, 3, 1-10, (2019).
- [3] D. Zhang, X. Wu, J. Chen, K. Lin, The development of collagen based composite scaffolds for bone regeneration, *Bioactive Materials*, 3, 1, 129–138. (2018).
- [4] X. Ke, Z. Zhuang, X. Yang, J. Fu, S. Xu, L. Xie, Z. Gou, G. Yang, Enhancing the osteogenic capability of core–shell bilayered bioceramic microspheres with adjustable biodegradation, *ACS Applied Materials & Interfaces*, 9, 29, (2017).
- [5] A.C. Souza, C. McNulty, J.A. Camilli, C.A. Bertran, M.M. De Souza, Calcium phosphate cement plus 10% wollastonite whiskers: an in vivo study. *Journal of Biomimetics, Biomaterials and Biomedical Engineering*, 47, 117–126, (2020).
- [6] G. Ma, D. Yang, Q. Li, K. Wang, B. Chen, J.F. Kennedy, J. Nie, Injectable hydrogels based on chi- tosan derivative/polyethylene glycol dimethacrylate/N,N- dimethylacrylamide as bone tissue engineering matrix, *Carbohydrate Polymers*, 79, 620–627, (2010).
- [7] G.G. Lima, J.K. Elter, B.S. Chee, W.L.E. Magalhães, D.M. Devine, M.J.D. Nugent, M.J.C. Sá, A tough and novel dual-response PAA/P(NiPAAM-co-PEGDMA) IPN hydrogels with ceramics by photopolymerization for consolidation of bone fragments following fracture, *Biomed. Mater.*, 14. (2019).
- [8] N. Peng, H. Yu, W. Yu, M. Yang, H. Chen, T. Zou, K. Deng, S. Huang, Y. Liu, Sequential-targeting nanocarriers with pH-controlled charge reversal for enhanced mitochondria-located photodynamic-immunotherapy of cancer, *Acta Biomaterialia*, 105, 15, 223-238, (2020).

- [9] B. Akar, B. Jiang, S.I. Somo, A.A. Appel, J.C. Larson, K.M. Tichauer, E.M. Brey, Biomaterials with persistent growth factor gradients in vivo accelerate vascularized tissue formation, *Biomaterials*, 72, (2015).
- [10] G. Jiang, J. Sun, F. Ding, PEG-g-chitosan thermosensitive hydrogel for implant drug delivery: cytotoxicity, in vivo degradation and drug release, *Journal of Biomaterials Science, Polymer Edition*, 25, 3, (2014).
- [11] T. Zhou, X. Li, G. Li, T. Tian, S. Lin, S. Shi, J. Liao, X. Cai, Y. Lin, Injectable and thermosensitive TGF-B1-loaded PCEC hydrogel system for in vivo cartilage repair, *Scientific Reports*, 7, (2017).
- [12] Q. Yan, L.Q. Xiao, L. Tan, W. Sun, T. Wu, L.W. Chen, Y. Mei, B. Shi, Controlled release of simvastatin-loaded thermo-sensitive PLGA-PEG-PLGA hydrogel for bone tissue regeneration: In vitro and in vivo characteristics, *J. Biomed. Mater. Res. Part A.*, 103, (2015).
- [13] Y. Ma, Y. Ji, T. Zhong, W. Wan, Q. Yang, A. Li, X. Zhang, M. Lin, Bioprinting-based PDLSC-ECM screening for *in vivo* repair of alveolar bone defect using cell-laden, injectable and photocrosslinkable hydrogels, *ACS Biomater. Sci. Eng.*, (2017).
- [14] K.O. Rivera, D.L. Cuylear, V. Duke, K.M. O'Hara, B.N. Kharbikar, A.N. Kryger, T. Miclau, C.S. Bahney, T.A. Desai, Localized delivery of β -NGF via injectable microrods accelerates endochondral fracture repair, *bioRxiv* (2021).
- [15] A. Ghimire, J.D. Skelly, J. Song, Micrococcal-Nuclease-Triggered On-Demand release of vancomycin from intramedullary implant coating eradicates *Staphylococcus aureus* infection in mouse femoral canals, *ACS Cent. Sci.*, 5, 1929-1936, (2019).
- [16] A.S. Azevedo, M.J.C. Sá, M.V.L. Fook, P.I.N. Neto, O.B. Sousa, S.S. Azevedo, M.W. Teixeira, F.S. Costa, A.L. Araújo, Use of chitosan and β -tricalcium phosphate, alone and in combination, for bone healing in rabbits. *Journal of Materials Science. Materials in Medicine (Dordrecht. Online)*, 25, 481-486, (2014).

- [17] P. Boodagh, R. Johnson, C. Maly, Y. Ding, W. Tan, Soft-sheath, stiff-core microfiber hydrogel for coating vascular implants, *Colloids and Surfaces B: Biointerfaces*, 183, (2019).
- [18] Y. Wang, S. Zhang, D.S.W. Benoit, Degradable poly(ethylene glycol) (PEG)-based hydrogels for spatiotemporal control of siRNA/ nanoparticle delivery. *Corel.* (2018).
- [19] M. Martin-Del-Campo, R. Rosales-Ibañez, K. Alvarado, J.G. Sampedro, C.A. Garcia-Sepulveda, S. Deb, J.S. Román, L. Rojo, Strontium folate loaded biohybrid scaffolds seed with dental Pulp stem cells induce *in vivo* bone regeneration in critical sized defects, *Biomater. Sci.*, 4, 1596-1604, (2016).
- [20] G. Asensio, L. Benito-Garzón, R.A. Ramírez-Jiménez, Y. Guadilla, J. Gonzalez-Rubio, C. Abradelo, J. Parra, M.R. Martín-López, M.R. Aguilar, B. Vázquez-Lasa, L. Rojo, Biomimetic Gradient Scaffolds Containing Hyaluronic Acid and Sr/Zn Folates for Osteochondral Tissue Engineering, *Polymers*, 14, 12, (2022).

CAPÍTULO II: Development and application of an association of wollastonite, β -TCP and PEGDMA based implant for the treatment of segmental bone defect in rabbits.

Trabalho a ser submetido à revista Biomaterials. ISSN: 0142-9612. Fator de Impacto: 15.3.
Qualis A3.

Development and application of an association of wollastonite, β -TCP and PEGDMA based implant for the treatment of segmental bone defect in rabbits.

F. A. Sousa Segundo^a, M. J. C. Sá^b.

^aPrograma de Pós-Graduação em Ciência e Saúde Animal, Universidade Federal de Campina Grande (UFCG), Av. Universitária, s/n, Bairro Santa Cecília, Patos, PB, Brasil.

^bUnidade Acadêmica de Medicina Veterinária, UFCG, Av. Universitária, s/n, Bairro Santa Cecília, Patos, PB, Brasil.

ABSTRACT

Attempts to repair large bone lesions are challenging, to facilitate this process it is possible to use biomaterials that stimulate tissue regeneration, with this objective to evaluate the potential of a composite based on β -TCP, Wollastonite and PEGDMA in the regeneration of bone defect. segmentation in rabbit radius, subjecting the composite to a stable environment of bone fracture. After obtaining the composites, in vivo evaluations were performed. Clinical, radiographic, tomographic and histopathological tests showed excellent biocompatibility, absence of cytotoxicity and evident stimulus to bone healing, such results are favorable to the use of the composite in the repair of bone segmental defects in environments with controlled stability.

KEYWORDS: Biomaterials; ceramics; Defect; Bone; polymers; Repair;

Introduction

The main causes of segmental bone defects in the medical routine are trauma, inflammation and neoplasms, such situations can lead to the loss of a large part of the bone stock, significantly complicating the treatment and worsening the prognosis of the lesion (Zhou et al., 2010).

The treatment objective is to reconstruct the bone column, causing the bone tissue to proliferate and fill the defect, in addition to providing mechanical resistance as early as possible, among the main complications found, there is non-union, delayed union, implant failure and osteomyelitis (Mabrouk et al., 2020).

Attempts to repair large bone lesions made several areas of knowledge join efforts to produce biomaterials capable of stimulating tissue regeneration in addition to promoting mechanical stability for the affected bone (Lin et al., 2010).

In vivo evaluations are fundamental to assess the properties and behavior of these biomaterials, some desirable properties of biomaterials include biocompatibility, bioactivity and absence of cytotoxicity (Barbosa et al., 2019).

Among the groups of biomaterials, ceramics such as Wallostonite and β -TCP are widely studied in the repair of bone tissue, this is due to the fact that the components of bioceramics are similar to the structure of the bone matrix, which favors the absorption of these materials (Rui Ge et al., 2019).

Polyethylene glycol dimethacrylate (PEGDMA) is a polymer widely used in the medical field with excellent biocompatibility and cell interaction properties, in addition, it has versatility in its manufacture, expanding the potential for application as a biomaterial (Lima et al., 2019).

The bone defects studied in rabbits and rats are the most reported in the literature, with several bones used, such as the femur, skull and radius, the latter presents itself as a great alternative for study, since the anatomical association of the radius with the ulna, allows greater stability to the limb when the fractures affect the radius or ulna alone (Lin et al., 2010).

In view of the above, the objective was to evaluate the potential of a composite based on bioceramics such as Wallostonite, β -TCP and PEGDMA in the regeneration of segmental bone defect in rabbit radius, subjecting the composite to a stable environment of bone fracture.

Materials and Methods

Obtaining biomaterials

The ceramics were prepared from a mixture of 80% Wollastonite (W), M400 NYAD® and 20% β -Tricalcium (β -TCP). β -TCP was obtained via precipitation by performing the neutralization reaction of Hydroxyapatite (analytical grade, LabSynth) with the required amount of Orthophosphoric Acid (analytical grade 85%, Panreac) to obtain a Ca/P ratio of 1.50. The resultant was then treated at 1000°C for 15 hours. Both the W (CaSiO_3) and β -TCP (Ca_3PO_4) ceramics were individually attrition milled.

The composites were prepared by the foam replication method (Teixeira et al., 2009). An aqueous suspension of 56% (wt) W- β -TCP powder in distilled water was prepared for foam impregnation. 0.3% by weight of dispersant (Dolapix PCN, Zschimmer-Schwarz) and 1% by weight of PVA binder (Optapix PAF 35, Zschimmer-Schwarz) were used to obtain a suitable suspension.

The 60 pore per inch (ppi) polyurethane foams were soaked with the suspension. The pieces were dried at 60 °C for 30 min and then sintered. The sintering schedule started with a slow heating rate, 2 °C/min up to 600 °C to avoid the explosive output of CO_2 resulting from the thermal decomposition of the polyurethane. Subsequently, the heating rate was increased to 5°C/min until the second stay at 1350°C for 2 hours. Then, the sintering and transformation of W into pseudo (ps)-W takes place (De Aza et al., 2006). However, at this temperature α -TCP is the stable phase, therefore, the transformation to β -TCP was promoted by cooling the ceramic composition to 1000 °C at a rate of 2 °C/min. The cooling rate must be slow to promote the phase transformation. On the contrary, α remains stable (De Aza et al., 2004).

PEGDMA and primer were weighed. PEGDMA was stirred in the magnetic stirring apparatus. Acrylic acid, distilled water and initiator were added to the beaker respectively and thoroughly mixed. After that, the mixture was placed in silicone molds and UV cured 18 hours by UV chamber (Dr. Gröbel UV-Elektronik GmbH). The UV chamber has a controlled radiation source that contains 20 UV tubes and the spectral range is 315 - 400 nm with an average intensity of 10–13.5 mW/cm².

In vivo study

The study was submitted to the Research Ethics Committee (CEP) of the Center for Rural Health and Technology of the Federal University of Campina Grande, Campus de Patos - PB (CSTR/UFCG) and approved under number 06/2021.

Twelve healthy New Zealand rabbits were studied, the animals were kept in an environment with temperature monitoring, housed in individual cages, receiving water and specific feed for the species ad libitum. During this period, they received a dewormer based on 1% ivermectin at a dose of 0.2 mg/kg, subcutaneously, and the administration was repeated after 7 days.

Experimental groups

Animals of similar age and weight were randomly divided into two experimental groups, the implant group (IG) received biomaterial implant and the control group (CG) did not receive any biomaterial. The experimental period was 120 days in total. After dividing the groups, the animals underwent a surgical procedure to create a fracture and apply biomaterials. Evaluations after surgical procedures were performed by evaluators who were unaware of the experimental groups.

Pre-surgical preparation

The animals had the forelimbs shaved broadly. They were submitted to a pre-anesthetic protocol consisting of 5% tramadol at a dose of 4 mg/kg, both intramuscularly, anesthesia was induced and maintained with the association of 10% ketamine at a dose of 40 mg/kg and xylazine at 2% at a dose of 4 mg/kg, both intramuscularly. Brachial plexus block was performed with 2% lidocaine at a dose of 9 mg/kg. The animals also received 20% ceftriaxone sodium at a dose of 30 mg/kg, administered intravenously 30 minutes before the surgical procedure, and 0.2% meloxicam at a dose of 0.1 mg/kg, subcutaneously. The administration of meloxicam at a dose of 0.1 mg/kg, subcutaneously, once a day, for 3 days, and tramadol at a dose of 4 mg/kg, intramuscularly, twice a day, were continued after the surgeries for 5 days.

Operative procedure

The right forelimbs were aseptically prepared, then the middle third of the radius and ulna was approached through a craniomedial skin incision, blunt subcutaneous divulsion and exposure of the radial periosteum. Osteotomy of a 5 mm radius segment was performed with the aid of a transverse oscillatory saw, and the defect was measured with a caliper. Then, a locked plate with 1.5 mm matched holes with 10 holes was applied, using two locked screws 1.5 mm in diameter and 10 mm in length. In the fracture focus of the right limbs, a biomaterial implant based on ceramics and PEGDMA (IG) was inserted, the implant was adjusted to occupy the 5 mm space left by the osteotomy. In the CG, the fractures of the left limbs were stabilized

with a similar plate and screws, but no biomaterial was implanted. Synthesis was performed with intradermal standard 3-0 polyglycolic acid thread and separate single standard 3-0 nylon thread. All surgical and anesthetic procedures were performed by the same team, in order to maintain the standard.

At the end of the procedure, a dressing was performed by cleaning with a 0.9% sodium chloride solution, gauze and tape, which was continued once a day for 10 days until the stitches were removed.

Clinical-orthopedic evaluation

Before the surgical procedures, data were obtained from the animals' normal ambulation, in order to establish a reference parameter. The animals were evaluated daily during the first 10 days after the procedure, then they were evaluated twice a week throughout the experimental period. The clinical-orthopedic evaluation took into account the ambulatory process of the animals (presence of lameness), painful sensitivity in the limb through palpation, muscle atrophy, presence of edema and adequate healing of the surgical wound.

Radiographic evaluation

Radiographs of the operated limbs were taken at four moments, immediately after the procedure, 30 days, 60 days and 120 days after the procedure. Radiographs were analyzed for bone axial axis alignment, apparatus integrity, biological activity of bone healing. For each variable observed in the radiographic examination, an observational scale was created with 1 – poor, 2 – partial and 3 – good.

Tomographic evaluation

After 60 and 120 days of the procedures, the animals were sacrificed using the anesthetic protocol described above and subsequent administration of potassium chloride intravenously. The forelimbs were collected and dissected, then the implants were removed to facilitate visualization of the fracture focus macroscopically and during the examination. Continuing, the samples were submitted to tomographic evaluation with a multi-slice helical series. The tomographic sections were evaluated for the presence of tissue neoformation and mineralization of the neoformed tissue. For each variable observed in the CT scan, an observational scale was created with 1 – mild, 2 – partial and 3 – intense.

Histopathological and morphometric evaluation

After the tomographic evaluations, macroscopic evaluations were carried out, aiming to visualize the continuity of the bone column and the absence of a fracture line. After the macroscopic evaluation, a sample of material was collected 1 cm above and 1 cm below the fracture site, the samples were fixed in 10% buffered formalin for 10 days. The segments, after fixation, were decalcified with a 6% hydrochloric acid solution for a period of 5 days. Then the fragments were dehydrated by passages in alcohol solutions in increasing concentrations (70%, 80%, 90% and absolute alcohol). Soon after, the materials were washed in running water and embedded in liquid paraffin and, later, cut into 5 μ m-thick transverse slices, then glass slides were mounted. From each block, four slides were obtained, which were submitted to hematoxylin-eosin techniques. For the histopathological evaluation, repair findings were relevant, observing the type of existing tissue (fibrous and/or bone), regularity of cortical bone and existing cellularity. For each observed variable, an observational scale was created with 0 – absent, 1 – decreased, 2 – intermediate and 3 – increased. For morphometric evaluation, imageJ software was used.

Statistical analysis

The data obtained were analyzed using the Bioestat 5.3 program, at a significance level of 5% and 1% ($p < 0.05$ and $p < 0.01$). Kruskal-Wallis test was used to compare non-parametric variables, while analysis of variance (ANOVA) followed by Tukey test was used for parametric variables. Data were presented as mean \pm standard deviation.

Results and Discussion

Clinical-orthopedic evaluation

After the operative procedures, all animals showed support of both limbs when standing and while walking on the first postoperative day. The animals allowed manipulation of the limbs, which were stable throughout the experimental period.

All animals showed edema until the second postoperative day, which regressed significantly after that. Muscle atrophy was not observed in any limb.

The surgical wounds healed after ten days, and stitches were removed from the limbs during this period. No signs of wound infection were observed during the experiment.

Most studies with segmental defects in the radius of rabbits used defects up to 1.5 cm in length, not reporting the need for stabilization of bone segments with implants, since the ulnar cortices were intact (CAPORALI et al., 2006). In the present study, stabilization with plates and screws was chosen due to the fact that both limbs were operated on and their use during ambulation could generate complications such as fracture of the ulna or severe misalignment of the bone segments.

Stabilization of radiuses with segmental defects using 5 mm plates and screws showed clinical results similar to those reported in studies without stabilization (MINTO et al., 2020). The preference for bones such as the radius for studies on segmental defects may be associated with greater stability of these bones when compared to other long bones, mainly due to the presence of the ulna.


Greater stability is essential to reduce complications and facilitate support after the procedure, bone tissue has piezoelectric properties that can respond to a mechanical stimulus, this makes the use of the limb after fracture stabilization procedures, favoring the healing process. healing of the bone (CARTER et al., 2021), for this reason it is important that patients who are in the process of bone healing are able to receive mechanical stimulation on the recovering bone.

Radiographic evaluation

The radiographs obtained during the experimental period showed the integrity of the apparatus used, plates and screws blocked, consequently maintaining bone alignment and stability (FIGURE 2).

On the other hand, the healing process differed between the groups, with progressive bone neoformation and decreased fracture focus at 60 days with total consolidation at 120 days postoperatively in the implanted group. In the control group, at 60 days postoperatively, resorption of the ends of the fracture focus was observed, promoting an increase in the fracture focus with subsequent proliferation of bone tissue, but with a significant defect on the radiograph even at 120 days (TABLE 3).

Figure 2 – Lateral radiographic images of the middle third of the radius and ulna of rabbits in the implant (IG) and control (CG) groups at different times after the surgical procedure. Bone defect region (red arrow).



The evaluated scores of the variables in both groups remained at 3 (good), with the exception of biological activity, which had mean scores of 2.5 ± 0.54 and 3 ± 0 for the implant group and mean values of 0.83 ± 0.75 and 1.6 ± 0.51 for the control group at 60 and 120 days (<0.05), respectively.

The maintenance of the environment at the focus of the defect or fracture can directly influence the bone healing process, maintaining the alignment of the fractured segments favors the direction of the repair and improves the result after healing (EGGER et al., 2014).

Table 3 – Mean values and standard deviation of radiographic evaluation scores of the implant groups (IG) and control group (CG) in relation to alignment, apparatus and biological activity at different times after the surgical procedure.

		Alignment	Apparatus	Biological activity
IG	0 days	3±0	3±0	0±0
	60 days	3±0	3±0	2,5a±0,54
	120 days	3±0	3±0	3a±0
CG	0 days	3±0	3±0	0±0
	60 days	3±0	3±0	0,83b±0,75
	120 days	3±0	3±0	1,6b±0,51

Means followed by letters differ statistically according to the Kruskal – Wallis test (<0.05) between the groups.

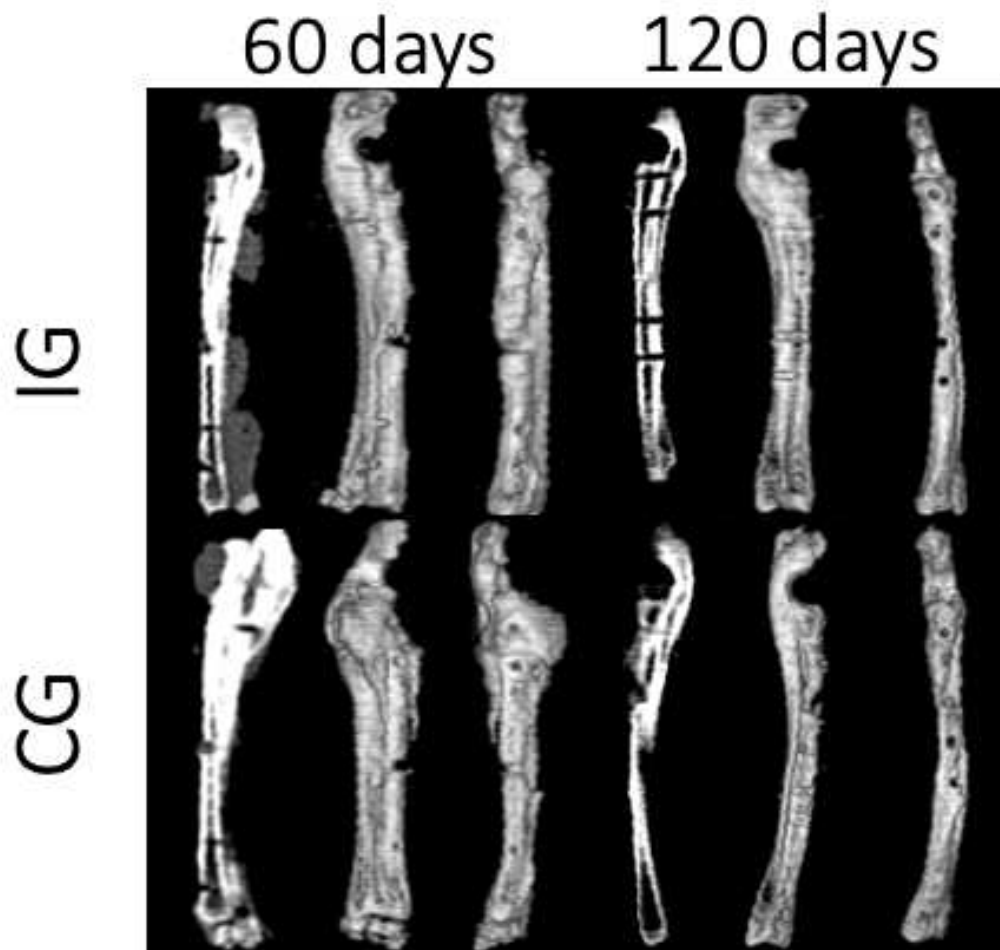
Although the defects studied in rabbit radius do not require additional stabilization, some alignment deviations can be observed during the bone repair process (JARDIM, 2018). In the present study, the use of plates and screws provided the standardization of movement at the fracture focus, in addition to providing adequate bone alignment throughout the experimental period observed by radiographs.

The progressive decrease in fracture focus observed in the implanted group on radiographs suggests excellent osteoinductive and osteoconductive properties of the materials, similar results are reported when using materials such as PEGDMA, wallostonite and β -TCP (YAN et al., 2015; SHI, et al., 2018; GE et al., 2019).

Tomographic evaluation

The tomographic evaluation at 60 days showed the presence of a fracture focus in both groups, however, in the implant group, a greater amount of newly formed bone tissue was observed in the fracture focus (FIGURE 3).

Figure 3 – Radio and ulna tomographic images of rabbits in the implant (IG) and control (CG) groups at different times after the surgical procedure.



At 120 days, the tomographic images showed no fracture focus in the implant group, the opposite was seen in the control group, with an evident fracture focus, still being observed resorption of the fracture focus extremities.

The evaluation of the tissue neoformation score obtained mean values of 2.33 ± 0.51 and 2.8 ± 0.4 for the implant group, while for the control group there were 1.33 ± 0.51 and 2 ± 0.63 at 60 and 120 days (<0.05), respectively (TABLE 4).

Table 4 – Mean values and standard deviation of tomographic evaluation scores of the implant groups (IG) and control group (CG) in relation to tissue neoformation and neotissue mineralization at different times after the surgical procedure.

		Tissue neoformation	Neotissue mineralization
IG	60 days	$2,33a\pm 0,51$	$2,16a\pm 0,4$
	120 days	$2,8a\pm 0,4$	$2,6a\pm 0,51$
GC	60 days	$1,33b\pm 0,51$	$1,1b\pm 0,40$
	120 days	$2b\pm 0,63$	$1,5b\pm 0,54$

Means followed by letters differ statistically according to the Kruskal – Wallis test (<0.05) between the groups.

Regarding the mineralization score of the neoformed tissue, mean values of 2.16 ± 0.4 and 2.6 ± 0.5 were obtained for the implant group and mean values of 1.1 ± 0.4 and 1.5 ± 0.54 for the control group at 60 and 120 days, respectively.

The tomographic evaluation is still little reported in this type of study, however, it can provide important information as it allows a more detailed assessment of the area studied (IRIE et al., 2018), the tomographic findings corroborate what was found in the radiographic evaluations and reveal that the implants favored, in addition to bone proliferation, the formation of a denser and more mineralized tissue during the studied period.

The stimulus to the neoformation of a denser bone tissue can be associated with the characteristics of the PEGDMA polymer, which has porosity that can facilitate the adhesion of

osteoblasts and osteoclasts, which use the ceramic matrix, favoring cell differentiation and the formation of mineralized regions. (PENG et al., 2017).

With cell adhesion in the PEGDMA-based composite, wollastonite and β -TCP ceramics stimulate the osteogenesis process due to the behavior of osteoblastic cells in increasing their activity on calcium phosphate surfaces, in addition, β -TCP has a specific property that promotes an adhesion of extracellular proteins that stimulate the proliferation and activity of osteoblasts (ASENSIO et al., 2022).

The period reported for complete healing of segmental defects in rabbits in several studies is between 60 and 120 days (CAPORALI et al., 2006). Although we observed bone proliferation in both groups throughout the experimental period, only the implanted group showed complete healing at 120 days, it is possible to observe that tissue neoformation progressed from the ulnar surface region and progressing through the radius surface.

The direction of bone healing observed in the present study is also reported in several studies (CIANI et al., 2006), this behavior may be related to the presence of periosteum over the ulnar cortex, which is not injured during the radial ostectomy procedure and is responsible for much of the bone vascularization.

In the control group, even at 120 days, complete healing of the fracture focus was not observed even during the tomographic evaluation, which differs from what has been reported in most studies (MOREIRA et al., 2014).

Histopathological and histomorphometric evaluation

The histopathological evaluation showed intense tissue proliferation both at 60 and 120 days in the implant group, a smaller amount was observed in the control group at both times. At 120 days, bone tissue neoformation was much more evident in the implant group (FIGURES 5 and 7) when compared to the control group (FIGURES 4 and 6). These findings are corroborated by the histomorphometric evaluation, revealing significantly higher values in the implant group at both times (TABLE 5).

At 60 days, it was still possible to observe the defects between the cortical bones, however, a decrease in size was visible in the implant group during this period. At 120 days, the defects in the implant group were practically closed, with the continuity of the cortical bones being observed, whereas in the control group, it was still possible to observe the presence of bone defect at 120 days. Intense neovascularization was also observed in the implant group, especially at 120 days when compared to the control group.

After the histomorphometric study, tissue proliferation could be quantified, with a statistical difference being observed between the experimental groups in both studied moments, with the implant group showing significantly greater tissue proliferation.

The evident stimulus to bone healing caused by implants can be justified by the composition of the materials, ceramics such as wallastonite and β -TCP have a composition similar to bone matrix, which allows them to be degraded and eventually incorporated into tissue neoformation (CIANI et al., 2006), which can serve as a basis for the repair of segmental bone defects.

The findings in the present study corroborate the reports of excellent biocompatibility and biodegradability properties of ceramics (RIVERA et al., 2021), these characteristics favor the application of these materials as direct stimulants for bone tissue repair as well as the application of composites of gradual release of substances and/or materials.

Table 5 – Mean values and standard deviation in μm of the histomorphometric evaluation of the implant groups (IG) and control group (CG) in relation to tissue quantification at different times after the surgical procedure.

	60 days		120 days	
	IG	CG	IG	CG
Mean	2031,67aB	1263,33bB	4798,33Aa	2408,33bA
Standard deviation	124,32	73,67	151,32	148,51

Means followed by lowercase letters (uppercase letters) differ statistically according to Tukey's test (<0.01) between groups (moments).

The absorption of the implants during the experimental period occurred gradually, no displacement or isolation of the implants was observed while the bone tissue was neoformed incorporating the implants, evidencing a direct stimulus to osteoinduction and osteoconduction, as reported by Deng et al., 2017 and Saadaldin et al., 2014.

Stimulating cell differentiation in osteoblasts and maintaining a framework for blood vessel neoformation is associated with both ceramics (KE et al., 2017), as well as polymers such as PEGMA, according to Frassica et al., (2019), polymers such as PEGMA can stimulate

increased levels of type 2 bone morphogenic protein and growth factors responsible for bone tissue neoformation.

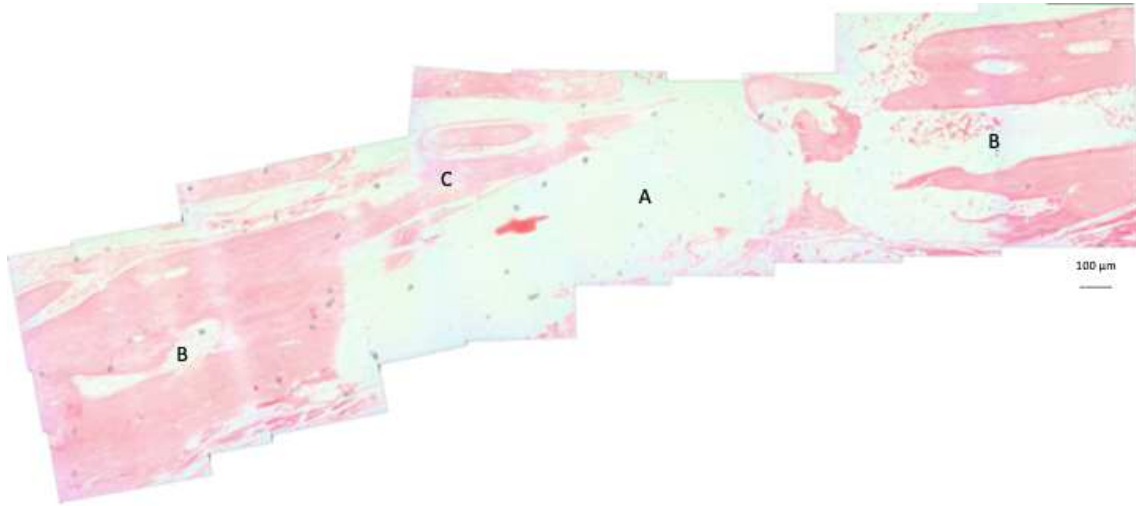


Figure 4 – Longitudinal histopathological section of the osteotomy site without implants at 60 days postoperatively. A defect (A) is observed between cortices (B), filled with little newly formed bone tissue (C). 40x magnification.

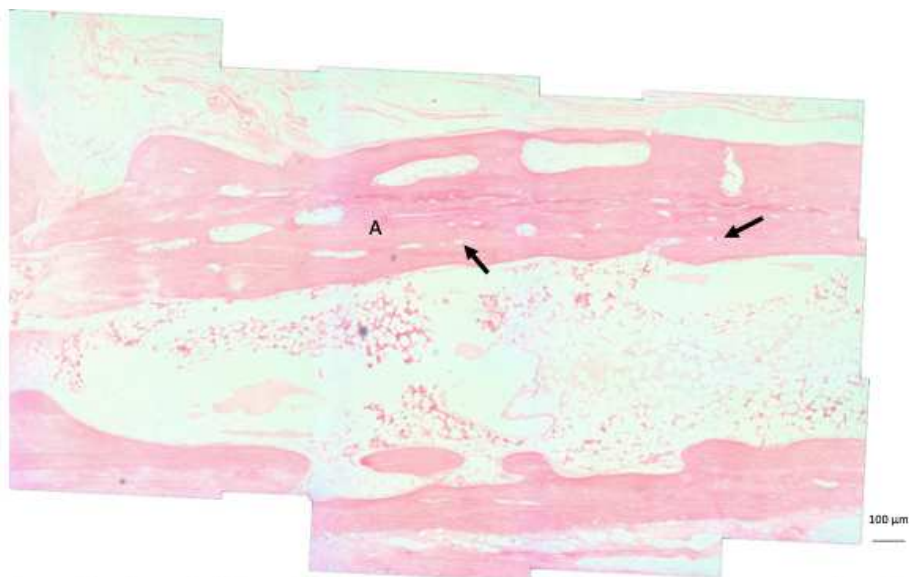


Figure 5 – Longitudinal histopathological section of the bone/implant interface at 60 days postoperatively. A large amount of newly formed bone tissue (A) in the process of maturation is observed, with some blood vessels (arrows) connecting the cortices. 40x magnification.




Figure 6 – Longitudinal histopathological section of the osteotomy site without implants at 120 days postoperatively. The presence of a defect (A) between cortices is observed, filled by moderate neoformed bone tissue (B). 40x magnification.

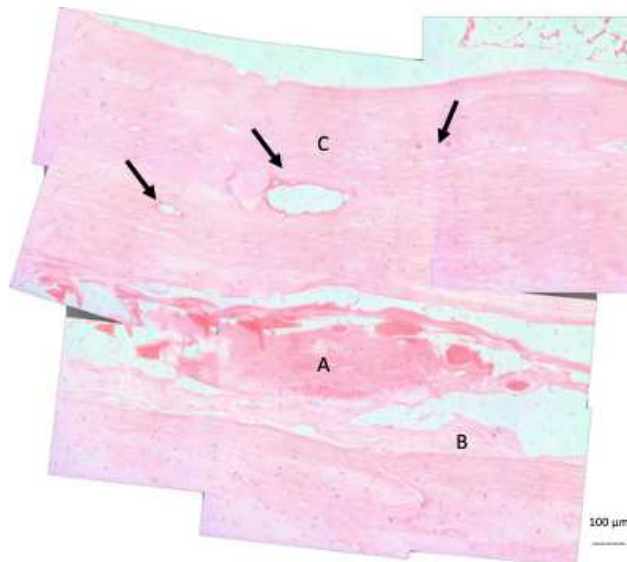


Figure 7 – Longitudinal histopathological section of the bone/implant interface at 120 days postoperatively. The presence of a remnant of biomaterial is observed (A), surrounded by little connective tissue (B). Above the biomaterial, an osteotomy region in an advanced stage of healing is observed, with the formation of more compact bone (C) and several blood vessels (arrows). 40x magnification.

The structural properties of polymers allow new blood vessels to reach the implants through their pores, along with angiogenesis comes the increase of undifferentiated cells which are stimulated to differentiate into osteoblasts and incorporate the mineral matrix of ceramics, similar results are reported by (ASENSIO et al., 2022).

The incorporation of bone matrix derived from bioceramics promotes an acceleration in tissue neoformation, allowing the filling of difficult-to-repair defects. MARTIN-DEL-CAMPO et al., 2016). This maturation makes the bone tissue denser and more load bearing, allowing for faster functional return to the limb.

Conclusions

In view of the findings of the present study, it is concluded that the study model of segmental defects in the radius of rabbits and stabilized with plate and screws is viable and can mimic routine clinical situations.

The use of a composite based on Wallostonite, β -TCP and PEGDMA clearly stimulated bone regeneration in segmental defects produced in the radius diaphysis of rabbits.

References

Asensio, G.; Benito-Garzón, L.; Ramírez-Jiménez, R.A.; Guadilla, Y.; Gonzalez-Rubio, J.; Abradelo, C.; Parra, J.; Martín-López, M.R.; Aguilar, M.R.; Vázquez-Lasa, B.; Rojo, L. Biomimetic Gradient Scaffolds Containing Hyaluronic Acid and Sr/Zn Folates for Osteochondral Tissue Engineering. *Polymers*, n. 14, v. 12. 2022.

Barbosa, W. T.; Almeida, K. V.; Lima, G. G.; Rodriguez, M. A.; Fook, M. V. L.; García-Carrodeguas, R.; Silva Junior, V. A.; Sousa Segundo, F. A.; Sá, M. J. C. Synthesis and in vivo evaluation of a scaffold containing wollastonite/ β -TCP for bone repair in a rabbit tibial defect. *Model. J. Biomed. Mater. Res.* 1-10, 2019. DOI: 10.1002/jbm.b.34462.

Caporali, E. H. G.; Rahal, S. C.; Morceli, J.; Taga, R.; Granjeiro, J. M.; Cestari, T. M.; Mamprim, M. J.; Correa, M. A. Avaliação de biomateriais bovinos contendo proteínas morfogenéticas ósseas absorvidas a hidroxiapatita em defeitos ósseos segmentares em coelhos. *Acta Cirúrgica Brasileira*, v. 21, n. 6, 2006.

Carter, A.; Popowski, K.; Cheng, K.; Greenbaum, A.; Ligler, F. S.; Moatti, A. Enhancement of bone regeneration through the converse piezoelectric effect, a novel approach fo applying mechanical stimulation. *Bioelectricity*, v. 3, n. 4, 2021.

Ciani, R.B.; Rahal, S.C.; Volpi, R.S.; Taga, R.; Granjeiro, J.M.; Cestari, T.M.; Mamprim, M.J. Mistura de proteínas morfogenéticas ósseas, hidroxiapatita, osso inorgânico e colágeno envolta por membrana de pericárdio no preenchimento de defeito ósseo segmenta em coelhos. *Arq. Bras. Med. Vet. Zootec.* V. 58, n. 1, p. 59-67, 2006.

De Aza, D.A.S. Biocerámicas. In: Sastre R, De Aza S, San Román J (eds). *Biomateriales*. Spain: Cooperación Iberoamericana, CYTED, *Biomateriales para la salud*; 2004. Pp. 291–322.

Deng, Y., Jiang, C., Li, C., Li, T., Peng, M., Wang, J., & Dai, K. (2017). 3D printed scaffolds of calcium silicate-doped β -TCP synergize with co-cultured endothelial and stromal cells to promote vascularization and bone formation. *Scientific Reports*, 7(1), 1-14.

Egger, E., Pluhar, E. Aceleração da cicatrização da fratura. In: BOJRAB, M.J. *Mecanismos das Doenças em Cirurgias de Pequenos Animais*. São Paulo: Roca, p.681-688, 2014.

Frassica, M.T.; Jones, S.K.; Diaz-Rodriguez, P.; Hahn, M.S.; Grunlan, M.A.; Incorporation of silicon-based Polymer to PEG-DA templated hydrogel scaffolds for bioactivity and osteoinductivity. *Acta Biomaterialia*, 2019.

Ge, R.; Xun, C.; Yang, J.; Jia, W.; Li, Y. *In vivo* therapeutic effect of wollastonite and hydroxyapatite on bone defect. *Biomed Mater*, v. 14, n. 6, 2019.

Irie M.S.; Rabelo, G.D.; Spin-Neto, R.; Dechichi, P.; Borges, J.S.; Soares, P.B.F. Use of micro-computed tomography for bone evaluation in dentistry. *Brazilian Dental Journal*, v. 29, n. 3, p. 227-238, 2018.

Jardim, P. H. A. Óxido de grafeno no reparo de defeito ósseo segmentar experimental em rádio de coelhos. 2018. 60p. Dissertação de Mestrado – Faculdade de Medicina Veterinária e Zootecnia, Universidade Federal de Mato Grosso do Sul, Campo Grande, 2018.

Ke, X., Zhuang, C., Yang, X., Fu, J., Xu, S., Xie, L., Gou, Z., Wang, J., Zhang, L., & Yang, G. (2017). Enhancing the osteogenic capability of core-shell bilayered bioceramic microspheres with adjustable biodegradation. *ACS Applied Materials & Interfaces*, 9(29), 24497-24510.

Lima, G. G.; Elter, J. K.; Chee, B. S.; Magalhães, W. L. E.; Devine, D. M.; Nugent, M. J. D.; Sá, M. J. C. A tough and novel dual-response PAA/P(nipaam-co-PEGDMA) IPN hydrogels with ceramics by photopolymerization for consolidation of bone fragments following fracture. *Biomed. Mater.* V. 14. 2019.

Lin, C. Y.; Chang, Y. H.; Lin, K. J.; Yen, T. C.; Tai, C. L.; Chen, C. Y.; Lo, W. H.; Hsiao, I. T.; Hu, Y. C. The healing of critical-sized femoral segmental bone defects in rabbits using baculovirus-engineered mesenchymal stem cells. *Biomaterials*. V. 31, 2010. Doi:10.1016/j.biomaterials.2010.01.030.

Mabrouk, M.; Taha, S. K.; Hamid, M. A. A.; Kenawy, S. H.; Hassan, E. A.; El-Bassyouni, G. T. Radiological evaluations of low cost wollastonite nano-ceramics graft doped with iron oxide in the treatment of induced defects in canine mandible. *J. Biomed. Mater. Res.* 2020, DOI: 10.1002/jbm.b.34767.

Martin-Del-Campo, M.; Rosales-Ibañez, R.; Alvarado, K.; Sampedro, J.G.; Garcia-Sepulveda, C. A.; Deb, S.; Román, J. S.; Rojo, L. Strontium folate loaded biohybrid scaffolds seeded with dental Pulp stem cells induce *in vivo* bone regeneration in critical sized defects. *Biomater. Sci.* v. 4, 1596-1604, 2016.

Minto, B. W.; Gonçalves Neto, J. A.; Sprada, A. G.; Quarterone, C.; Sartori, M. R., Alcântara, B. M.; Hespanha, A. C. V.; Uscategui, R. A. R. A critical size defect. Model in the radius of rabbits. *Ars. Veterinaria*, v. 36, n. 3, 2020.

Moreira, R.; Dória, R.G.S.; Camargo, L.M.; Santos, M.D.; Minto, B.W.; De Nardi, A. B.; Ambrósio, C.E.; Freitas, S.H. Aspecto radiológico e macroscópico de matriz óssea mineralizada heteróloga fragmentada e polimetilmetacrilato autoclavados em falha óssea de tibia de coelho. *Pesquisa Veterinária Brasileira*, v. 34, n. 2, p. 173-178, 2014.

De Aza, P.N.; De Aza, A.H.; Herrera, A.; Lopez-Prats, F.A.; Pena, P. *Journal of the American Ceramic Society*, 2006, 89, 8, 2619.

Peng, S.; Feng, P.; Wu, P.; Huang, W.; Yang, Y.; Guo, W.; Gao, C.; Schuai, C. Graphene oxide as an interface phase between polyetheretherketone and hydroxyapatite for tissue engineering scaffolds. *Scientific Reports*, v.7, 2017.

Rivera, K. O.; Cuylear, D. L.; Duke, V.; O'Hara, K. M.; Kharbikar, B. N.; Kryger, A. N.; Miclau, T.; Bahney, C. S.; Desai, T. A. Localized delivery of β -NGF via injectable microrods accelerates endochondral fracture repair. *Biorxiv* 2021. Doi: <https://doi.org/10.1101/2021.11.16.468864>.

Rui Ge, Xun, C.; Yang, J.; Jia, W.; Li, Y. *In vivo* therapeutic effect of wollastonite and hydroxyapatite on bone defect. *Biomed. Mater.* V. 14, 2019. <https://doi.org/10.1088/1748-605X/ab4238>

S. Teixeira, M.A. Rodriguez, P. Pena, A.H. De Aza, S. De Aza, M.P. Ferraz and F.J. Monteiro, *Materials Science and Engineering C*, 2009, 29, 5, 1510.

Saadaldin, S. A., Dixon, S. J., & Rizkalla, A. S. (2014). Bioactivity and biocompatibility of a novel wollastonite glass-ceramic biomaterial. *Journal of Biomaterials and Tissue Engineering*, 4(11), 939-946.

Shi, Y.; Liu, J.; Yu, L.; Zhong, L.Z.; Jiang, H.B. β -TCP scaffold coated with PCL as biodegradable materials for dental applications. *Ceramics International*, v. 44, n. 13, 2018.

Yan, Q.; Xiao, L-Q.; Tan, L.; Sun, W.; Wu, T.; Chen, L-W.; Mei, Y. Shi, B. Controlled release of simvastatin-loaded thermo-sensitive PLGA-PEG-PLGA hydrogel for bone tissue regeneration: *in vitro* and *in vivo* characteristics. *Journal of Biomedical Materials Research part A*, v. 103, n. 11, 2015.

Zhou, J.; Lin, H.; Fang, T.; Li, X.; Dai, W.; Uemura, T.; Dong, J. The repair of large segmental bone defects in the rabbit with vascularized tissue engineered bone. *Biomaterials*, v. 31, 2010. Doi:10.1016/j.biomaterials.2009.10.043

CONCLUSÕES

Os compósitos a base de Wollastonita, B-TCP e PEGDMA se mostraram eficientes para estimular o reparo de defeitos ósseos segmentares em raios de coelhos.

A utilização de ensaio utilizando defeito segmentar em rádio de coelhos estabilizado com placas e parafusos se mostrou satisfatório para avaliar a regeneração de defeito ósseo segmentar.